

# **Comparing Two Methods of Surgical Treatment Planning with Mini Dental Implants**

**Patricia Mara Bandeira de Oliveira**

School of Graduate and Postdoctoral Studies  
Faculty of Dentistry  
McGill University  
Montreal, Quebec, Canada

June 2012

*A thesis submitted to McGill University in partial fulfillment of  
the requirements of the degree of Master of Science*

Copyright © 2012 Patricia Mara Bandeira de Oliveira

# 1. Table of Contents

---

2.	Abstract .....	1
3.	Résumé .....	3
4.	Acknowledgements .....	5
5.	Literature Review .....	7
5.1.	Surgical guide for dental implant placement .....	7
5.2.	CT Scans .....	12
5.2.1.	Cone Beam Computed Tomography and imaging software .....	16
5.3.	Prototyping in dentistry .....	18
5.4.	Computer-Guided Surgery for Dental Implant Placement .....	22
5.5.	Flapless surgery for dental implant placement .....	25
5.5.1.	Mini Dental Implants adding value to the flapless technique .....	28
6.	Rationale and Study Objective .....	31
7.	Material and Methods .....	33
7.1.	Ethical Standards .....	34
7.2.	Inclusion and Exclusion criteria .....	34
7.3.	Prescreening phase .....	36
7.4.	Screening Phase .....	36
7.5.	Complete Denture Duplication .....	37
7.6.	Surgical guide fabrication .....	39
7.7.	Planning the angulation and position of the implants using a Conventional method .....	40
7.8.	Assessing the CBCT scan images .....	43
7.9.	Planning the position of the implants using dental implant treatment planning software .....	47
7.10.	Assessing the difference in position and angulation between the implants planned with the Conventional and Software-based methods .....	48
7.10.1.	Discrepancies in the bony entrance points .....	49

7.10.2.	Discrepancies in angulation.....	52
7.11.	Statistical analysis .....	56
8.	Results .....	57
9.	Discussion .....	61
10.	Conclusions.....	67
11.	Reference List .....	<b>Error! Bookmark not defined.</b>

## 2. Abstract

---

**Objective:** This study evaluated the discrepancies between dental implant treatment planning for surgical guide fabrication using Cone Beam Computerized Tomography (CBCT) with imaging software and a Conventional method based on anatomic landmarks and prosthetic design. **Methods:** Based on anatomical landmarks in the interforaminal area, four metal guiding sleeves were installed in radiographic templates fabricated on mandibular casts for placement of 64 implants in 16 patients (n=16). Each patient enrolled in the study underwent a CBCT scan with the template in the mouth. The metal sleeves were identified in the tomogram, and their positions were compared to the positions of implants virtually determined with the implant treatment planning software. Using specific tools provided by the software, differences in bony entrance points and angulations, in the mesial-distal and labial-lingual directions, were measured for each implant. Median differences were compared using Wilcoxon signed rank test for clustered data. **Results:** Median differences (interquartile ranges) of the entrance points based either on anatomical landmarks or imaging software were 0.8 ( $\pm 0.0$ –0.85) mm in the mesial-distal direction and 0.7 ( $\pm 0.0$ –5.0) mm in the lingual-labial direction ( $p < 0.001$ ). A significant angle difference was observed between the two methods in the mesial-distal and labial-lingual directions ( $p < 0.001$ ). The median (interquartile range) differences in angulations between the two methods were 2.2 (0.0–10.05) degrees and 4.9 (0.0–18.7) degrees ( $p < 0.001$ ), respectively. **Conclusion:** Planning the placement of implants using CBCT

imaging software leads to different implant location and angulations than with conventional treatment planning based on anatomical landmarks; these differences may have an impact on clinical outcomes.

### 3. Résumé

---

**Objectif :** Cette étude évalue les différences entre la planification de traitements avec implants dentaires utilisant un guide chirurgical fabriqué à l'aide de la tomographie volumétrique numérisée 3D (Cone Beam Computed Tomography, CBCT) et d'un logiciel d'imagerie, et l'utilisation d'une méthode conventionnelle basée sur des repères anatomiques et sur la conception de prothèses. **Méthodes:** En se basant sur des repères anatomiques de la région interforaminale, quatre manches métalliques servant de guide ont été installés dans des modèles de radiographie fabriqués sur moule mandibulaire pour le placement de 64 implants chez 16 patients ( $n = 16$ ). Chaque patient participant à l'étude a passé un examen CBCT avec le modèle dans la bouche. Les manches en métal ont été localisées sur le scan, et leurs positions ont été comparées aux positions d'implants déterminées avec le logiciel de planification d'implants. En utilisant des outils spécifiques fournis par le logiciel, les différences entre les points d'entrée osseux ainsi que les angulations, dans les directions mésio-distale et bucco-linguale, ont été mesurées pour chaque implant. Les différences médianes ont été comparées en utilisant le test des rangs signés de Wilcoxon pour échantillons appariés. **Résultats:** Les différences médianes (intervalles interquartiles) des points d'entrée basés soit sur la méthode des repères anatomiques ou la méthode du logiciel d'imagerie étaient de 0,8 (0,0 à 0,85) mm dans le sens mésio-distal et 0,7 (0,0 à 5,0) mm dans la direction linguale-labiale ( $p < 0,001$ ). Une différence d'angle significative a été observée entre les deux méthodes dans les directions

mésio-distale et labial-linguale ( $p < 0,001$ ). Les différences médianes (intervalle interquartile) des angulations entre les deux méthodes étaient de 2,2 (0,0 à 10,05) degrés et 4,9 (0,0 à 18,7) degrés ( $p < 0,001$ ) respectivement. **Conclusion:** La planification du placement des implants à l'aide d'un logiciel d'imagerie CBCT a pour résultat une variation dans le positionnement et l'angulation des implants en comparaison à la planification du traitement en utilisant la méthode conventionnelle basée sur les points de repère anatomiques. Ces différences peuvent avoir un impact sur les résultats cliniques.

## **4. Acknowledgements**

---

This work has been a result of the efforts of a number of individuals who have supported the process of bringing my thesis to completion. For their dedication and commitment I would like to thank them and acknowledge their contributions.

Firstly, my special gratitude is due to my supervisor, Professor Dr Rubens Albuquerque, who was generously helpful and offered irreplaceable assistance, support and guidance. I would like to thank him for the opportunity he has given me not only to develop this study, but also to initiate in the academic carrier.

I have deepest gratefulness to my co-supervisor Dr Jocelyne Feine, for all her inputs, invaluable guidance and useful comments at various stages in the preparation of this thesis.

I am also extremely grateful to all the patients who were part of this study. I thank them for their time and readiness to participate.

Special appreciations also to our partners Cesar Oleskovicz, Bioparts company owner, who provided us with technical support, to Dr Jose Correa, for the biostatistics expertise we counted on, and to Dr Fernando Leite, for all the ideas shared, conversations and feedbacks regarding radiology technologies.

I would like also to acknowledge with thanks 3M ESPE and The Fonds de la Recherche en Santé du Quebec (FRSQ) for providing me with scholarships that enabled me to move forward in my studies.



Finally, the most special thanks go to my best partner and friend, the one who has made the many hours spent in my office seem worthwhile after all, my husband. Aguinaldo Diniz, you gave me your unconditional support and love throughout this long process. Te Amo.

## **5. Literature Review**

---

### **5.1. Surgical guide for dental implant placement**

Also known as radiographic/surgical templates, surgical guides for dental implant placement are devices employed to ensure adequate implant orientation into the bone tissue, according to the restorative treatment planning and patient's anatomy. It has been reported that the use of surgical guides decreases the risks associated with complex surgeries and difficult prosthetic reconstructions, while increasing the long-term success rates of the treatments with implants (1-4) .

The need for esthetics and predictable prosthetic treatment results guided the advance of a new concept of “prosthetically driven implantology”, which establishes that the optimal position of implants is related not only to internal anatomy, but also to biomechanics and the final prosthesis design (5-7). Occlusal forces following the long axes of the implants are considered a key factor for maintenance of osseointegration and favorable biomechanics, diminishing the risks of complications and increasing the longevity of the implant treatment (8).

Since the 1980s, many studies describing different techniques for surgical guide fabrication have been published (9-12). In 1987, Edge et al. recommended the use of surgical guides before implant placement surgery. In fact, the author advocated the use of a small bleeding mark with a sterile surgical instrument at the position indicated by a guiding template before implant placement (13). Another study described a technique for the fabrication of surgical guides that orients the

surgeon to a suitable location and angulation of the implant, including palpation of the potential implant site as a step in the planning phase. It was also suggested local anesthesia to insert a needle through the soft tissue to the bone so that the gingival thickness could be measured on different sites of the alveolar ridge (14).

Guerrero et al. (2006) reported that only when used in combination with a thorough and comprehensive radiological estimation will the clinician be provided with the necessary data to safely plan and perform implant placement procedures (15).

Minoretti et al. (2000) described a process of fabricating surgical guides and implant placement, whereby the position of the implants was prosthetically determined (16). In this process, Kirschner (Synthes/Stratec, Oberdorf, Switzerland) wires were placed through the mucosa before flap reflection followed by a surgical guide, to serve as reference for an osteotomy with proper location and angulation. It was suggested that this technique would allow a better communication between prosthodontist and surgeon and that this was a feasible technique, even for practitioners with restricted skills.

A surgical template must be translucent, rigid and stable, and should be easy to sterilize and insert in the mouth. Although surgical templates brings many advantages to the surgeon, some drawbacks are also present such as the risk of bone overheating due to the obstruction of the cooling system and the existence of some instability, especially in fully edentulous patients, in which the template is only supported by the mucosa (17). Also, a sum of errors during template

fabrication such as the distortion of digital images and improper template positioning during the surgery, may lead to lack of accuracy (18).

Tarlow et al. (1992) suggested that surgical templates should have a relief at the buccal flange to fit the reflected flap, and the lingual flange trimmed to allow easier access to the surgical field so that the template would be supported mainly by the patient's mandibular pads and remaining tissues (19). In this technique, proposed for edentulous mandibles, the patient's denture was duplicated with transparent acrylic resin and a clear polypropylene stent was made over it in a vacuum-forming machine. Next, the whole anterior segment of the duplicate denture was removed in order to expose the surgical area and the vacuum stent was perforated at the planned implant sites and adapted over the denture to guide the bone drilling.

Neidlinger et al. (1993) described the fabrication of a modified surgical guide in which instead of holes or grooves placed on the lingual flange of a duplicated denture the stent was reduced in the areas where the implants were to be placed, preserving only the vestibular part of the denture (20). The authors suggested that this method would allow better control of the implants' buccal/lingual angulation and their placement in an optimal position for prosthetic rehabilitation.

An advance in the fabrication of surgical guides was accomplished with the use of radiopaque materials mixed with acrylic powder in order to provide contrast and facilitate the evaluation of references for implant positioning when using imaging techniques (21-23).

Another method developed to improve the precision and functionality of surgical guides was the introduction of telescopic tubes to guide the drill during the osteotomy. Balshi et al. (1987) proposed a surgical guide for cases of complete edentulism made of a duplicate denture with 2 mm diameter plastics tubes inserted (Pindex Die System, Whaledent International) (24). However, it was not clear in their report how the positions of the implants planned in the cast were transferred to the plastic tubes embedded in the surgical guide. The authors emphasized the need to pay special attention to irrigation and cooling of the surgical burs during the treatment and that once the first drill was used, the template was of little value, with the preparation being completed freehand.

In order to facilitate communication between the surgeon and the restorative dentist, methods that combine radiographies and surgical guides have been proposed.

Engelman et al. (1998) described a method in which a temporary complete denture was fabricated in order to evaluate esthetic outcomes and used as a surgical guide (25). The resulting surgical guide had metal bearings embedded in the acrylic resin for tomographic assessment. After imaging evaluation and before surgery, the inserted metals and the lingual flange of the guide were removed.

Many other methods for surgical guide fabrication with markers have been reported with some variations, including the use of gutta-percha, vertical lead strips, set-up disks and metal tubes, many times used as both radiographic markers and drill guides during implants placement (26;27).

Different approaches for surgical guide fabrication with emphasis on stability have been advocated. The use of surgical templates stabilized by mini-implants is a recent method that has been recommended by some investigators, especially for completely edentulous ridges (28-31).

In a case report, it has been found that stabilizing surgical templates with provisional implants can increase the accuracy of implants placement, mainly when multiple implants are inserted in a completely edentulous mandible (28). In this report, metal tubes were inserted in a surgical template, mesial and distal to the position of the mental foramina, to orient the placement of permanent and transitional implants. The tubes were positioned away from the location planned for the permanent implants, and arranged in a configuration that allowed both stabilizing the template and preventing injuries to the alveolar nerve. Another study showed that if the patient has a satisfactory interocclusal distance, the stabilizing implants do not need to be totally immersed into the bone, making their insertion easier (29).

Sicilia et al. (2000) evaluated the outcomes of the treatment with implants placed with the aid of fixed or movable surgical templates (30). Aiming to compare fixed surgical template to the movable ones, 28 implants were installed in slightly resorbed edentulous maxilla and their positions were compared to patients-controls who had similar bone morphology, but whose implants were inserted using movable surgical templates. There was a significantly higher frequency of coincidence between the planned implant positions and the positions

obtained with surgical templates stabilized by transitional implants (93%) in comparison to the non-stabilized ones (64%).

An advantage of using transitional implants is to provide temporary retention/support for provisional prostheses during the healing phase with the permanent implants (32;33). On the other hand, this technique has some drawbacks, such as the risk of aspiration of the transitional implant during surgery, the challenge of placing the conventional implants between the transitional ones, increased cost, and increased laboratory and chair times (30;31).

## **5.2. CT Scans**

Intraoral examinations along with panoramic and periapical radiographs were largely utilized as resources for planning the insertion of dental implants. However, planning a dental implant surgery with radiographies has been found to have limitations such as little information regarding bone volume and density. Also, panoramic radiographic images can present distortions, which are associated with a deficiency in sharpness (34;35).

Different techniques have recently been developed in order to minimize morbidity and the chance of implant failure and to increase predictability of the implant placement. Within that context, computerized tomography (CT) has become a major diagnostic tool, making the surgical/prosthetic implant treatment planning easier and more accurate (3). With the use of a CT scan, the surgeon has

a pre-operative three-dimensional (3D) view of the surgical field available for treatment planning instead of the two-dimensional image seen in the conventional radiography. A three-dimensional view allows the simulation of alternative treatment approaches and a more precise evaluation of the associated anatomy.

The possibility to have an accurately dimensioned 3D view of the subject in high resolution - under a millimeter - is the main advantage of the CT exam over the two dimensional imaging systems (36). Reddy et al. (1994) compared the difference in distortion and magnification of images that were to be used in dental implant treatment planning and found a statistically significant difference between the range of magnification of the CT images (0 to 6%) and panoramic radiographies (25%) (34). Digital radiographs show some enhancements in terms of image and bone measurements, but still provide limited information to detect pathologies and to localize important anatomic structures (37). CT scans provide a three-dimensional perspective of the jawbones and vital structures which far exceeds that of conventional two-dimensional radiography.

Conversely, the dose of radiation applied to perform diagnoses with CT scans and its long-term consequences are, currently, under intense debate (38;39). Clinicians and patients should have a clear idea regarding the risks of the radiation involved in CT scans. Given that the doses from the majority of CT scan machines are currently higher than that of a conventional dental radiograph, it is important to define an effective, low dose radiation that leads to a quality image (40;41). The ALARA (As Low As Reasonably Achievable) is a radiation security principle for decreasing radiation doses recommended for implementation in the clinic. The



principle advocates justification for indication of exams with tomograms, optimization of surveys and limitation of dose levels as protective measures against radiation in dentistry and medicine (42). It has also been recommended that professionals requesting and performing tomographic exams be updated on the current literature concerning radiation effects, dosage and related equipment, and emphasis be placed onto reducing patients exposure to radiation as much as possible, while preserving an acceptable image quality (43).

Schorn et al. (1999) developed a protocol for CT scans in dentistry to allow clinicians to obtain high-quality images with as low radiation doses as possible (44). Using mandibles of two human skeletons and 39 patients, different tube currents (from 40 to 200 mA), and two different exposure techniques (axial and helical modes) they measured radiation doses and defined the most valuable protocol. It was verified that the protocol using axial mode with 130 mA produces radiation dosage 3 times greater than the protocol that uses the helical technique with 80 mA and 2 pitches, with no differences in image quality. The authors concluded that the use of low-current tubes and helical scan mode is recommended for dental CT scans.

Another study reported an implant treatment planning protocol aimed to aid clinicians in achieving an acceptable compromise between image quality and dose of radiation. In this protocol, the scanned field should be limited to the arch evaluated; the occlusal plane should be parallel to the floor; the patient should be kept immobile during scanning; and a small-volume element size, the voxel, which allows for better visibility of anatomical structures, should be chosen (45).

On the other hand, some investigators found that radiation doses vary widely and that the real problem is not the amount of radiation the patient receives in one session, but the number of exams done without any rationale. According to Hall and collaborators (2008), the individual risks are considered small, but the increase in CT usage by health professionals has been cause of real distress and may become a potential public care issue in the future (46).

With the advent and popularization of CT scans as an aid for diagnosis and treatment planning in dentistry, methods of surgical guide fabrication allied to high-quality imaging and use of software have been advocated. In 1991, a manually fabricated surgical guide based on CT scan images was presented by Modica et al. (47). In this *in vitro* study, a CT scan was performed after the fabrication of a surgical guide, which followed a diagnostic wax-up. According to reference points seen in the image, a mathematic calculation was performed in order to evaluate the scope of adjustments. After adjustments, implants were placed in the mandible, and a second CT scan was performed to evaluate the accuracy of the procedure, which demonstrated an angular error of 4 (average of 1.3) degrees and a horizontal error of 1.5 mm (average of 0.4 mm).

Many studies proposing techniques for surgical guide fabrication using CT scan image have been published. However, there is paucity of investigations on the precision of surgical guides fabricated based on the information gathered from CT scans and imaging software (48-52).

Among the few authors who developed studies under this perspective are Besimo et al. (2000). They compared the positions of implants planned with CT

scans and in corresponding study casts of 77 sites of the mandible or maxilla, and found discrepancies of 0.3 mm (SD = 0.4) in the mandible and 0.6 mm (SD = 0.4) in the maxilla (53).

Other authors have suggested that radiopaque templates could be used as surgical guides and even as provisional restorations (52;53). Wat et al. (2002) developed a dual-purpose radiographic template/surgical guide with 3 mm diameter channels prepared and filled with gutta-percha. CT scans were made with the templates in the patients' mouths and the differences between the positions and angulations of the implants indicated by the gutta-percha and the ones planned with imaging software were calculated mathematically and corrected using a parallelometer. The authors suggested that the procedures were considered straightforward and accurate, with no demand for complex equipment or skills, and that metallic guiding tubes could also be used to replace the gutta-percha (52).

#### **5.2.1. Cone Beam Computed Tomography and imaging software**

Cone Beam Computed Tomography (CBCT) is a recently developed imaging technology dedicated to the jawbone structures that uses lower levels of radiation dosage in comparison to conventional CT machines. A typical exam of the maxilla and/or mandible requires the equivalent amount of radiation necessary for a radiographic full-mouth periapical series, but with higher longitudinal and axial resolutions (15). It differs from the conventional CT machines in some other aspects, such as weight, cost, scan time, and the final resolution of image (54;55).

Negative aspects of the CBCT are the relatively high cost of the procedure and lack of accuracy for soft tissue evaluations (56). Still, it has been the examination method of choice for preoperative purposes, especially when the benefits to the patient compensate for the risks of the exposure to ionizing radiation (58).

Added to the CBCT scan, computer software is available to depict and convert the DICOM files (the raw data generated by the CBCT) into a high-quality three-dimensional image, which allows clinicians to perform diagnoses and treatment planning within a suitable level of accuracy. Also, CT scan imaging software can improve the communication within an interdisciplinary team and between the clinician and patient.

Examples of imaging software are:

1. Artma Virtual Implant TM (VISIT) - (Vienna General Hospital, University of Vienna, Vienna, Austria).
2. coDiagnostiX (IVS Solutions AG, Chemnitz, Germany)
3. Easy Guide (Keystone-dental, Burlington, MA, USA)
4. Implant LogicsTM (Implant Logic Systems, Ltd., Cedarhurst, NY, USA)
5. ImplantMasterTM (I-Dent Imaging Ltd., Hod Hasharon, Israel)
6. Procera Software® (Nobel Biocare, Goteborg, Sweden)
7. Siplant®, SurgiCase® (Materialise Inc., Leuven, Belgium)

The current software applications have tools that enable clinicians to simulate the placement of implants, using trans-sectional, panoramic and 3D views. They allow the diagnosis of bone morphology and quality, and the detection of anatomic landmarks (57).

Many studies relating the usefulness of CBCTs for bone density diagnosis have been published on the consistency of CBCTs to determine bone density (57-59). Gonzalez-Garcia & Monje (2012) performed biopsy in 39 maxillary bones from 31 patients of sites where dental implants had been inserted and compared the results to the CBCT analysis performed pre-operatively. It was observed a strong positive correlation between the two analysis suggesting that CBCT could be used for pre-surgery estimation of bone density (60). Hohlweg-Majert et al. (2011) combined 3D image analysis from CBCTs and the Lenkholm and Zarb's classification for bone density in order to investigate bone quality and quantity of the retromolar region of pigs' mandibles. The authors concluded that although CBCT was successful on bone mass estimation, it could not deliver reliable data on bone quality (61).

### **5.3. Prototyping in dentistry**

One of the latest technological developments in the biomedical field is the advent of the rapid prototyping technique, a modeling process used to create an object from a digital file by depositing layers of specific materials such as acrylic-based photopolymers. With the widespread use of CT scans and modern software, rapid prototyping has become something tangible for dentists (62;63).

Transferring the position planned for an implant using CT scan imaging software to the surgical field is an issue to be addressed. With the aid of diagnostic

casts, clinical exams, CT scan images and software, the number of implants, their axes, angles, sizes and distribution can be determined, having bone availability, anatomic structures and final prosthetic requirements under consideration. However, errors have been reported between the position planned for implants using these tools and the position that they actually achieved in the surgical field (64).

In order to overcome this issue, clinicians began using computer-aided design and computer-aided manufacturing (CAD/CAM) systems as an alternative to handmade surgical templates. This prototyping technique had mostly been used to customize prosthetic fixed restorations, namely onlays, inlays, veneers, crowns and implant abutments (65).

Balshi et al. (2006) described a protocol for use with CT scans and the CAD/CAM technology. They illustrated some advantages of using this technique, such as the short working time for delivery of patients' final prostheses with minimum need for adjustments. The authors concluded that these techniques represent a significant advancement in implant dentistry and prosthodontics (66).

In the stereolithographic method, a prototyping model is created from a 3D image of the patient's scanned prosthesis or a diagnostic wax-up, so all the characteristics, such as adaptation, border extensions and occlusion, are reconstructed in the surgical template. This technique allows the fabrication of computer-generated surgical templates that are set with the individual depth, angulation, mesial-distal and labial-lingual positioning of the implants, as determined in the 3D computer planning. A laser combined with UV-light

projection is mounted on top of a vat containing liquid photo-polymerized resin that moves in increments of 1 mm, while the laser beam polymerizes the resin according to the preplanned prosthesis or implant design (67).

Many studies describing different techniques for computer-controlled surgical guide fabrication have been published (66;68-71). Fortin et al. (2000) described a process of implant placement planning involving the use of CT scans and the Cadimplant<sup>®</sup> software (Praxim, Grenoble, France), which is also known by the commercial name Easy Guide<sup>®</sup> (Keystone-dental, Burlington, MA, USA). A resin cube containing two titanium tubes was inserted into the patient's mouth during the CT scan, and its position was recognized and repeated by system in the drilling machine. Consequently, a mathematical link between CT image and drilling machine is determined (71).

Another clinical study involving 30 partially or completely edentulous patients used the above-mentioned protocol for surgical guide fabrication (72). The results suggested that computer-manufactured surgical guides associated with software programs have consistent accuracy in diagnosis and implant treatment planning.

The accuracy of stereolithographic models has been subject of several investigations (73-77). An *ex vivo* study evaluated the accuracy of stereolithographic models in four cadaver jaws (78). Data from CT scans were used to plan the fabrication of stereolithographic models. Pre and post-operative CT images were matched, and the deviations between implants' angulations and positions were examined. Images from inserted implants showed angular and

linear deviations of 2 (SD: 0.8, range: 0–4.0) degrees and 1.1 (SD: 0.7, range 0.3–2.3) mm, respectively, in relation to the planned references. In another investigation, deviations from the computer-based planned position were also found after implant placement. CT scans were performed before and following the placement of 94 implants planned using stereolithographic templates. Special software fused both images, allowing the planned position of the implants to be compared to those actually placed. The mean angular difference was 4.9 (+/-2.36) degrees and the linear difference was 1.22 (+/-0.85) mm at the implant neck. These values were considered clinically negligible and the authors suggest that micro-movements of the surgical guide during the surgery might be the reason for the discrepancies (79).

The stereolithographic method for surgical guide fabrication is considered very accurate, which improves the productivity and quality of the templates. However, the major drawback of this technique is the high investment in laboratory and clinical work and, consequently, the increase on treatment costs (80).

A survey evaluated the surgeon's view of the benefits with stereolithographic models for diagnosis, treatment planning, performing preoperative surgery and surgical procedures (81). It was found that 69% of the surgeons used these models for diagnostic purposes and that 92% used them for treatment planning. There was a decrease in the duration of the surgery, according to 77% of the surgeons, and more complex procedures were realized with more



safety and confidence. Nevertheless, only 15% of the participants considered the stereolithographic model an essential tool for the patient's treatment.

A similar study evaluated the indications and benefits of stereolithographic models using a 50-item questionnaire answered by surgeons in charge of 466 different cases involving implant placement. The models were used during the pretreatment and treatment phases. It was reported that the surgeons evaluated the stereolithographic models as being time-saving and as a tool that improved the quality of diagnosis and facilitated communication between the surgeon and patient (82).

#### **5.4. Computer-Guided Surgery for Dental Implant Placement**

The aim of the navigated surgery is to guide the surgeon, in real time, to localize anatomical structures or pathologies and to guide the use of surgical instruments in minimally invasive surgeries. It consists of a computer workstation and a system that calculates the position and orientation of a surgical instrument. Data collected by the system are displayed on the CT image, which provides the surgeon with information on the position of the instrument and neighboring anatomic structures (83).

Active surgical guidance based on surgical navigation is the most sophisticated method for surgery performance. It was initially used in neurosurgery and in ear, nose, throat and orthognatic surgeries, tumor surgery,

punctures, biopsies and the removal of foreign bodies (84-86). Currently, a clear trend towards the use of computer-guided surgery in implantology has been observed. Commercial companies have developed navigation systems with hardware and software specifically designed to aid in the positioning and insertion of dental implants. (87;88)

From a methodological point of view, navigation can be performed using different instruments and techniques:

1. A position-sensitive mechanical arm, such as the Viewing Wang (ISG Technologies, Mississauga, Ontario), is a device with movable angles and a stylus at the tip, which holds the instrument and calculates its position data. The arm has some degree of freedom that allows it to move in the surgical field. The arm position is converted into space orientation and position, which are shown in the CT preoperative images and allow assessment during surgery (85). This system offers an acceptable level of precision, but has the disadvantages of requiring space at the operating table and restricting mobility (89).

2. Electromagnetic field-base: radiation-free sensors are attached to surgical instruments. They measure their spatial location in real time. Each sensor detects the magnetic field emitted by the closer transmitter and sends the data back to a workstation, which calculates its exact position and orientation (90). The advantages of this system are that very small detectors are used and there is no need for visual contact between the instrument and the system's sensor. However, this system can experience interferences from external magnetic fields and metal instruments (91).

3.        Ultrasound can be used as an alternative to improve intraoperative orientation in regions with soft tissue and used as an instrument for pathologic findings (92). These systems, such as the Echo Blaster (128 INT-1Z, Teled, Vilnius, Lithuania), are composed of an ultrasound probe and a coordinate tracker allied to navigation software (93). Although precise, the accuracy of this system may be influenced by air movement, background noise and obstructions in the sound path (94).

4.        Video-optical: this system is becoming standard in navigated surgeries. It uses an infrared camera to monitor surgical instruments and the patient's head position. These cameras track the position of infrared light-emitting diodes (LED) that are placed on the instruments and on a headset worn by the patient during the surgery (95). These data are sent to the workstation. The drawback of this system is the need for regular visual contact between the camera and the instruments and the propensity to receive interference from light reflections and metallic surfaces. Also, it has been considered a very expensive system (94).

Sieûegger et al (2001) compared the accuracy of computer-assisted implant treatment planning and surgery to conventional methods (96). Five patients underwent CT scans wearing headgear that contained radiopaque marks as reference points for the patient's position in the operating room. Panoramic radiographs and mounted casts were used to conventionally plan implant locations and to fabricate a template. The optimized implant position planned with computer-assisted system planning tools was then compared to the positions

conventionally planned. It was reported that conventional planning underestimated bone availability and required many changes in position during the surgery in order to avoid bone perforation. The authors concluded that optical tracking system with infrared light based navigation offers a high accuracy at all times during the surgery and has the potential to become routine in planning and inserting implants, especially in anatomically difficult surgical sites.

Different other studies report the superiority of computer assisted planning systems added to interactive implant placement over the systems based on two-dimensional systems and standard planning for dental implants (97-101).

Some authors have stated that the use of a navigating system may be limited by financial constraints, but it helps the surgeon to avoid injury to sensitive anatomical structures and wrongly positioning implants, especially in very complex surgeries, via the elimination of possible manual errors (102). In addition, surgeons that foresee performing the gold standard of minimally invasive surgeries, the flapless technique, have their abilities enhanced with the use of this technology (103;104).

## **5.5. Flapless surgery for dental implant placement**

During implant placement surgery, a muco-periosteal flap is usually raised in order to allow the direct visualization of the bone, surrounding tissues and anatomic structures. Bone visualization using this technique helps the surgeon to make a final decision regarding bone availability and quality, which may

influence the implant treatment outcomes. However, the raised flap and consequent sutures may lead to post-surgery undesirable instances, such as discomfort, pain and swelling. Also, it may increase the probability of bone or gingival margin loss (105).

In order to fulfill the current requirements of esthetics and comfort, a minimally invasive and less traumatic technique to place implants has been advocated. The flapless technique is a surgical method in which a flap is not raised on the surgical field and the implants are “blindly” placed (106).

According to some investigators, the flapless technique presents advantages, such as less distressing surgery; reduced operating time; reduced number of post-operative complications, with a quicker period of healing, and improved patient comfort (107-109). In addition, it has been reported that the minimized access for implant placement leads patients to have minimal bleeding during the surgery, that the interdental papillae and the gingival margin of the adjacent teeth are preserved, and that the possibility of bone resorption caused by the full-thickness periosteal flap is eliminated (108;110).

However, in addition to the impossibility of visualizing anatomical landmarks and the implant receiving site, the flapless technique presents other potential drawbacks, such as the risk of bone overheating due to limited cooling during the osteotomy, the impossibility of performing alveoloplasty and the difficulty of managing keratinized mucosa around the implant (111).

Historically, the flapless technique used to depend on the surgeon training and experience since the implant receiver site is chosen mostly according to the

alveolar bone outline observed during the surgery. According to Campelo & Camara (2002), before the procedure becomes a routine practice, the surgeon passes through a learning curve. This blind method may lead to bone perforation or fenestration, so patient selection must base on the presence of favorable bone width(112). The lack of preoperative planning may also lead to other consequences, such as the loss of hard and soft tissues or deficiency of prosthetic space (113).

For the above-mentioned reasons, alternatives aimed at facilitating implant position planning have been suggested. One example is the involvement of computer tomography and navigated surgery with this surgical technique (114-116). Using sophisticated methods, the surgeon can accurately assess anatomic limitations and the quality and availability of bone and to determine the best position for implant placement and foresee the restorative results with flapless approaches (117).

Malo et al. (2007) reported the association of the flapless technique to computer-guided implant surgery with a preliminary evaluation of bone loss and survival (118). One year after the placement of 92 implants supporting fixed complete prosthesis, the survival rate was around 98% and the average bone loss was 1.9 mm, which indicated that the method, when used for completely edentulous patients, was extremely efficient and predictable.

In a retrospective clinical study, Berdougou et al. (2010) compared 271 implants placed using a flapless protocol to 281 implants placed using a conventional flapped procedure (115). After a follow up period of four years,

there was no statistical difference ( $p=0.14$ ) between groups. It was concluded that flapless procedures do not interfere with the osseointegration because there were only a small number of implant failures in both groups.

#### **5.5.1. Mini Dental Implants adding value to the flapless technique**

The use of a non-traumatic technique for implant placement, such as the flapless technique, was favored by the development of implants with reduced diameters. According to Sohrabi et al. (2012), the term mini dental implant, or simply MDI, have been commonly used for implants with diameters ranging from 1.8 to 4.0 mm (119). They have recently been developed and used for several purposes:

1. Single tooth replacement: one mini-implant can replace a tooth in a narrowed edentulous area due to the inclination of the neighbor teeth long after extraction without the necessity of prosthetic preparation of those teeth, bone graft surgery or orthodontic treatment (120).
2. Orthodontic treatment: partially edentulous patients or the ones with congenital dentofacial anomalies can receive mini implants for orthodontic anchorage. The osseointegrated implant provides the clinician with a stable structure for the application of orthodontic forces in order to carry out even the most difficult movements, acting as an ankylosed tooth (121). After orthodontic treatment, the implant can also be used for prosthetics purposes (122).

3. Transitional implants: used for immediate stabilization and retention of provisional prosthesis – usually the patient's existing dentures – during the process of healing and the osseointegration of the definitive implants (123;124). Also, it may protect the sites for healing and maintain the vertical dimension while the definitive overdentures are not in place (125). Transitional implants are removed in the end of the treatment.

4. Fixation of surgical guides: mini-implants are inserted with a noninvasive technique in order to stabilize a template to the bone, used to guide the implant placement during surgery. Consequently, the template will be kept in the correct position, especially when there is considerable bone resorption and other tissue changes, a demand for insertion of many implants in an edentulous ridge, or in cases where the locations of the implants are critical for the restorative phase of the treatment (28).

5. Support/retention of overdentures: overdentures supported by mini-implants have been especially useful for arches with advanced bone resorption and for patients requiring immediate stabilization of their dental prosthesis. The treatment with mini implants also presents lower costs, technical simplicity when compared to regularly-sized implants and a survival rate reported in a retrospective evaluation as of 95.3% (126).

In addition to facilitating minimally invasive surgical procedures, mini-implants can be immediately loaded with the mechanical forces of a transitional or permanent prosthesis. A minimum degree of implant stability, which is the lack of implant movement in lateral directions, must be achieved in this case (127). Bone



quality is an additional prerequisite for immediate loading, along with an adequate preparation of the bone site (128;129).

Specific studies have been carried out to verify the success of overdentures supported by mini-implants. In one of these studies, Griffiths et al. (2005) assessed 24 patients and evaluated the acceptability of their overdentures supported by mini-dental implants (130). Of 116 implants placed, 97.4% were considered successful after 13 months. Based on the results from questionnaires, the authors concluded that there was improvement not only in comfort, chewing and speaking abilities, but also in postoperative satisfaction.

Ahn et al. (2004) studied 11 patients with fully edentulous mandibles who had a total of 25 mini-dental implants inserted in order to retain immediate temporary removable or fixed prosthesis (131). The success rate after a period of 21 weeks was approximately 90%. The authors concluded that using mini dental implants in order to retain temporary prosthesis provides many benefits: it protects the final implants and bone grafts in the healing period and allows immediate mastication and esthetics for patients.

A multicenter biometric analysis measured the success/failure rate of treatments involving 1029 MDI mini-dental implants over a period of eight years. An average of 8.83% mini-dental implants failed to stabilize, which confirmed the hypothesis that mini-dental implants could be used to deliver a reliable level of implant treatment success (132).

## **6. Rationale and Study Objective**

---

The use of CBCT scans and imaging software has become a fully recognized modality of implant treatment planning in terms of image quality, linear measurements and accuracy (3;15;18;34;36;45;133). It has allowed the development of CAD/CAM techniques, steriolithographic models and navigated surgery, which are considered predictable and precise methods for planning and performing dental implants placement, especially when a flapless technique is required. However, chair time and costs involved with these techniques are still considered significantly high (81;134).

Methods conventionally used for surgical guide fabrication based on anatomical landmarks that can be identified clinically, on models and radiographs are relatively simple and provide clinicians with a rapid and financially feasible approach to dental implant treatment planning with little radiation exposure (135-138).

Despite the extensive use of conventional methods for surgical guide fabrication in the general practice, controlled assessments of the results obtained with these techniques are still scarce. Direct comparisons with more modern and supposedly more accurate implant treatment-planning approaches, such as methods based on CBCT scan and imaging software, are lacking.

Therefore, the aim of this study was to compare a conventional method for dental implant treatment planning and fabrication of surgical guides based on anatomic landmarks, models and radiographs with a method based on CT Scans

and imaging software for dental implant treatment planning. Linear and angular differences (in millimeters and degrees, respectively) between the two methods were quantified. The null hypothesis that there were no statistical differences between the two methods was tested.

## **7. Material and Methods**

---

In this prospective paired-compared study, a convenience sample of 16 patients with a mean age of 66.87 years (range 55 to 85) was selected from a larger pool of patients recruited from the general population in Montreal and surrounding areas for the evaluation of mandibular overdentures supported by four mini dental implants (MDI).

Radiographic/surgical templates were initially fabricated based on anatomical references identified on models obtained from impressions of the patients' mandibular arches, according to a "conventional" method (13;13;19;22). Bony entrance points and angulations of implants planned for placement were transferred to the templates using metallic sleeves, which later served as radiographic markers for Cone Beam Computed Tomography (CBCT) scan exams. Implant treatment planning based on the CT scans and imaging software was performed for the same patients. The resulting positions and angulations planned for the implants obtained with the two different methods were then compared.

Discrepancies observed between implants positions and angulations obtained before and after digital planning were, therefore, the study's dependent variables.

## **7.1. Ethical Standards**

McGill's Institutional Review Board approval (A10-M118-09A) was obtained prior to commencing the study. All patients signed a written informed consent before registration for participation in the study. Each subject reserved the right to withdraw from the study at any time.

## **7.2. Inclusion and Exclusion criteria**

In order to be included in the study, the patients had to:

- Be completely edentulous, with the last tooth extraction having occurred 1 year ago or more;
- Have requested implant stabilization of the existing lower conventional denture;
- Have adequate space in the anterior mandible for the placement of four IMTEC MDI mini dental implants;
- Be wearing acceptable complete dentures regarding peripheral seal, extension and adaptation, teeth wear and ability to maintain adequate oral hygiene and clean dentures;
- Have a systemic health status that permitted minor surgical procedures;
- Have an adequate understanding of written and spoken English or French;
- Be capable of giving written informed consent;

- Have a minimum vertical mandibular bone height of 13 mm in the interforaminal region.

Subjects were excluded from the study if:

- There was a lack of minimum vertical mandibular bone height of 13 mm in the interforaminal region;

- They had acute or chronic symptoms of parafunctional disorders;

- They had a history of radiation therapy to the orofacial region;

- They were or had been taking bisphosphonate IV;

- They had health conditions that may jeopardize treatment, such as alcoholism, smoking etc.;

- They were taking any phenytoin (Dilantin), cortisone or insulin;

- They had a severe/serious illness that requires frequent hospitalization;

- They had impaired cognitive function;

- They were unable to return for evaluations/study recalls.

### **7.3. Prescreening phase**

Patients recruited from a pool of respondents to newspaper advertisements passed through a telephone-prescreening interview. During this phase, patients answered to a questionnaire. The ones that fulfilled the inclusion/exclusion criteria were accepted for the clinical screening phase.

### **7.4. Screening Phase**

During the clinical screening phase, potential patients filled out questionnaires on their health condition and sociodemographic characteristics. Patients' general and oral health status, quality of hygiene maintenance as well as the condition of their complete dentures, regarding extension and adaptation of the denture bases, teeth wear, vertical dimension of occlusion, and presence of parafunctional habits, were evaluated by a prosthodontist and noted in specific forms. The height of the mandibular bone in the anterior area was evaluated clinically by palpation, and also in a panoramic radiography. Patient having at least 10 mm of mandibular bone height as seen on the radiograph were accepted in the study.

In order for a flapless surgery to be carried out with safety, the study's panel of experts, based on the 3M IMTEC surgical protocol, developed clinical criteria for inclusion in the study, where the patient should present:

- At least 8 mm of mandibular anterior ridge width;
- At least 13 mm of mandibular anterior ridge height;

- Muscles on the floor of the mouth attached at a level that would allow the clinician to palpate the lingual incline of the mandible.

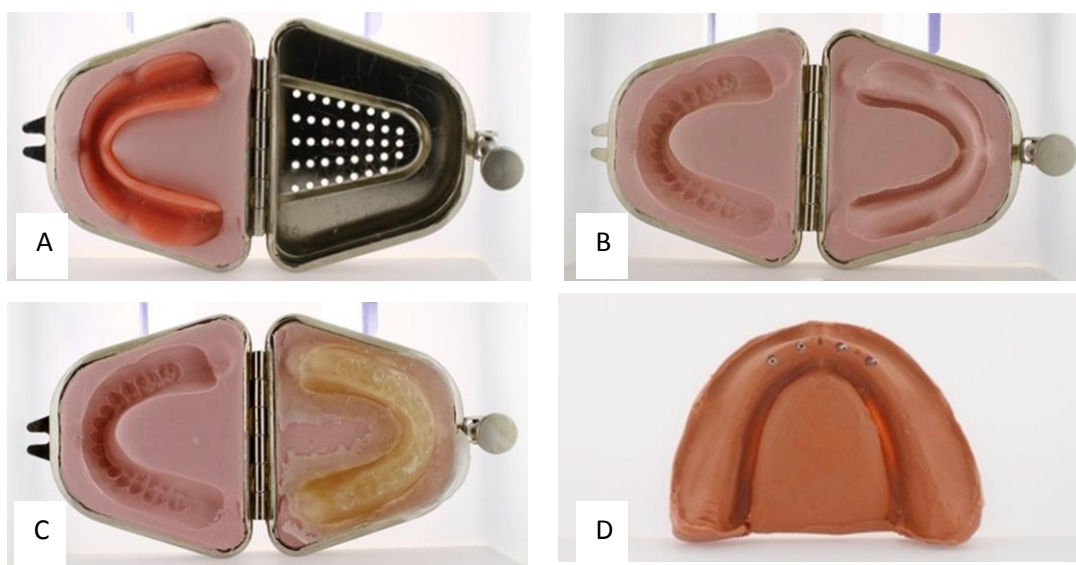
## **7.5. Complete Denture Duplication**

In the first clinical appointment, the patient's mandibular denture was duplicated for fabrication of the radiographic/surgical template. The duplication was performed following the method described by Neidlinger et al. (1993) (20). In brief, one half of a metal flask for denture duplication (Lang Dental Manufacturing, Wheeling, Illinois, USA) was loaded with irreversible hydrocolloid Alginate (Jeltrate Plus, DENTSPLY, Milford, USA); the denture was inserted halfway into the mixture, with the teeth and labial-lingual acrylic surfaces of the denture base being embedded by the Alginate (Figure 1 A). After setting, the other half of the flask was completely filled with additional material and the flask was closed, allowing the alginate to penetrate inside and around the denture base. When the second half of the Alginate set, the flask was opened, the denture removed, and the recording inspected (Figure 1 B). Only complete recordings with no major bubbles or defects were accepted, otherwise the process was repeated. The space occupied by the denture was then filled with transparent acrylic resin (Caulk Orthodontic Resin, DENTSPLY Caulk, Milford, USA). The flask was closed again and placed in a pressure pot (Aquapress, Lang Dental Manufacturing, Wheeling, Illinois, USA) filled with cool tap water. After the polymerization



period, the flask was opened (Figure 1 C), the excess acrylic trimmed off and the denture replica finished and polished.

A hydrophilic addition reaction silicone impression material (Aquasil Easy mix Putty, DENTSPLY, Milford, USA) was poured into the denture replica, to create a model of the patient's alveolar ridge (Figure 1D).



**Figure 1 A to D: Complete denture duplication.** **A:** Denture teeth and labial-lingual acrylic surfaces of the denture inserted halfway into the alginate mixture. **B:** View of the internal and external surfaces of the denture recorded in alginate. **C:** Flask with the duplicated denture in transparent acrylic resin. **D:** A model of the patient's alveolar ridge created using a mix a hydrophilic addition reaction silicone impression material made from the denture replica. Note the presence of four metal rods inserted into the silicone material in the anterior ridge used to indicate the position and angulation planned for implants placement. Pictures gently taken by Dr. Ovidiu Ciobanu.

## **7.6. Surgical guide fabrication**

Using the complete denture duplicate, a radiographic/surgical template was fabricated according to Tarlow et al. (1992) with modifications: A plastic vacuum shell (Sta-Vac II Vacuum Forming System, Buffalo Dental Manufacturing Co., Inc., Syosset, NY) was fabricated over the teeth of the duplicated denture, then removed and trimmed. The anterior teeth and the first pre molars of the duplicate denture were cut off with acrylic burs (Acrylic Trimming Bur, Miltex-Integra Miltex, USA), and the acrylic base reduced to a thickness of about 6 millimeters.

The plastic shell had the anterior teeth filled with a radiopaque material (barium sulfate) according to the method developed by Basten et al (48; 49): the shell was filled with a fluid mixture of one part of barium sulfate with two parts of acrylic resin powder added to acrylic resin monomer. When the resin was polymerized, the radiopaque teeth duplicate was removed, cut and trimmed to the contour of the teeth, put back into the plastic shell, and held in place with sticky wax. This plastic shell with the radiopaque duplicate was used to allow the visualization of the teeth volumes on the tomography (19).

Also, random parts (small boxes) of the internal surface of the denture base had the acrylic trimmed off and replaced by the same mixture of barium sulfate and acrylic resin in order to show the denture base contour in the CBCT image.

### **7.7. Planning the angulation and position of the implants using a Conventional method**

In this study, “Conventional method” was considered the one used to determine the best position of implants and fabricate surgical guides according to procedures that have been commonly used and described in the literature, based on palpation, clinical judgment, and prosthetic parameters and anatomic landmarks (17;19;23;139), along with the 3M IMTEC surgical protocol (140).

According to the 3M IMTEC surgical protocol, the bony entrance points of adjacent implants should be located between 5 to 8 mm apart, and 7 mm far from the mental foramen, differently for standard sized implants protocol, where the distance between the most distal implant and the mental foramen should be of 2 mm (141). Also, according to the 3M protocol and other reports, four is considered the minimum number of mini implants that should be used in mandibular overdentures and six mini implants are required to retain a maxillary overdenture (142-144), whereas two standard implants are enough to retain an overdenture, being the placement of four implants in the interforaminal region indicated only for narrow mandibular arches (145). Data from panoramic radiographies were taken into account when defining the mesial-distal position of the implants and locating the mental foramen position. Taking into account potential variations in the normal anatomy of the mandible, the first implants on each side were placed 5 mm from the midline and the second 6 to 8 mm distally to the first ones.

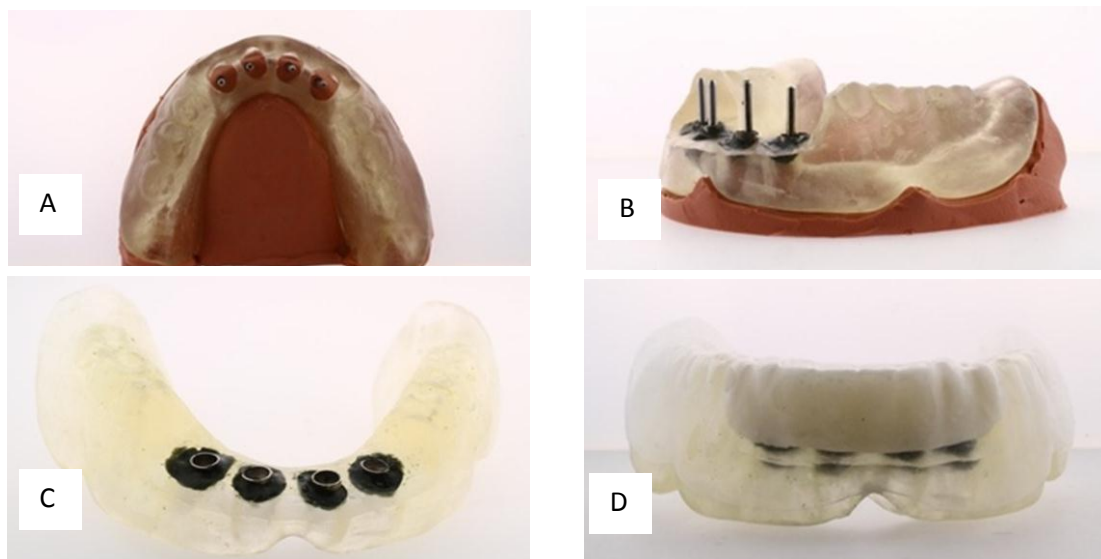
The outline and position of the denture teeth were considered when defining the angulation of the MDIs, in an attempt to prevent excessive discrepancy between the long axis of the implant and the direction of the occlusal force of mastication. Also, the bulkiness of the denture base and teeth was taken into account when establishing the labial-lingual position of the implant: the acrylic resin thickness around the attachment metal housing was set to be no less than 1 mm in order to achieve a safe installation of the attachment component in the denture base without weakening it.

After registering the position of each implant with a marker on the silicone model, thin metal rods were inserted into the ridge to mimic the desired position and angulation of each implant (Figure 1 D).

Perforations were then created in the surgical guide at the respective positions using cylindrical acrylic burs. These holes were large enough to fit stainless steel tubes (4.0 mm outside diameter x 3.5 mm inside diameter; Vita Needle Stainless Steel Needles and Tubing, Massachusetts, USA) that were used as markers for CT scans and drill guides for future surgical use.

Next, the surgical guide was placed over the silicone base with the metal rods passing through the holes in the acrylic resin (Figure 2 A). Subsequently, the metal tubes were fastened into the holes with a thermoplastic material compound (Kerr Corporation, California USA) following the direction of the metal rods inserted into the silicone base (Figure 2 B, C and D). The use of a thermoplastic material allowed adjusting the position and direction of the metal tube as necessary.

With the tubes in place, the surgical template was finished and tried in the patient's mouth to verify its adaptation to the residual ridge and relationship with the maxillary complete denture. In the respective clinical session, the patient's maxillomandibular relationship was registered with Jet Bite (Coltene/Whaledent, Switzerland) in maximal intercuspation. The resulting registration was stabilized on the template with cyanoacrylate-based adhesive in order to facilitate repositioning of the surgical guide in the patient's mouth during the CBCT scan exam.



**Figures 2 A to D: Surgical guide fabrication with metal tubes for guidance of the implants positioning according to the Conventional method.** A: Duplicate denture sited over the silicone-based model of the patient's alveolar ridge with references marked for measurements. Perforations were created to fit stainless steel tubes (4 mm outside diameter x 3.5 mm inside diameter) used as markers for CBCT scans. B: Lateral view of the surgical guide on the silicone model, with the metal tubes embedded in a thermoplastic material compound in which rods were inserted to indicate the positions for implants placement. C: Frontal view of the guide with the metal tubes stabilized by the compound. D: Surgical guide finalized, with the vacuum shell filled with radiopaque material for indication of the denture teeth volumes on the CBCT scan. Pictures are a courtesy of Dr. Ovidiu Ciobanu.

## **7.8. Assessing the CBCT scan images**

Each patient was submitted to a CBCT scan in a Gendex machine (Gendex Dental Systems, Hatfield, PA, USA) having the template previously described positioned in the mouth.

The Gendex CB 500 is a dental maxillofacial imaging system that has a scan time of 5, 8.9, 14.7, or 26.9 seconds and a reconstruction time of 20 seconds. This device has a standard field of view of 2, 4, 6, or 8 cm height x 8 cm depth, and an X-Ray source of 120 Kvp and 3-7 mA (pulsed). It acquires 360 images at 1° interval, with a resolution of 14 bites per pixel.

The divergent rays exiting the machine are received by a digital receptor. This information is three dimensional in volume and undergoes reconstruction to form a pile of axial images named DICOM images (Digital Imaging and Communication in Medicine).

The initial volume of data acquired by the scanner, the pile of axial images, can be specifically reformatted through mathematical algorithms in order to calculate each of the other planes. These raw data, the DICOM file obtained from the tomography, are converted to images that can be viewed in three planes: (1) axial (X) plane, a plane that runs parallel to the ground and divides the body into superior and inferior parts; (2) coronal (Y) plane, a vertical plane that runs perpendicular to the ground and divides the body into anterior and posterior sides ; and (3) sagittal (Z) plane, a vertical plane that runs perpendicular to the ground and divides the body into right and left side. These three images, when viewed

together, are referred to as multiplanar reconstructed images (MPR images), which provide precise measurements of the patient with a 1:1 ratio relationship.

The Dental Slice<sup>®</sup> software (Bioparts Biomedical prototyping, Brasilia, Brazil), used for diagnosis and treatment planning, enables the user to reformat data from the pile of axial images and view these different planes through windows named axial, cross, panoramic and 3D views (Figure 3). On the software screen, each window shows a cross-reference to the other windows in the form of indicators. These indicators are lines showing, in a determined window, references to the other ones.

On the axial window, two indicators are seen: the panoramic curve and the cross line. The panoramic curve is a line that is placed following the curve of the patient's alveolar ridge. It is used to show which slice is being displayed in the panoramic view and divides the patient's mandible in anterior and posterior parts. The cross indicator is a blue line that runs perpendicular to the panoramic curve indicator and is used to show which slice is being displayed in the cross window (Figure 3 B).

A frontal view of the patient can be seen through the panoramic view, which is the projection of the mandible in one plane resulting in flatness of the mandible outline. This reformatting is created through the extrusion of the panoramic curve. So, the panoramic image is a controlled distortion of a tridimensional space, since the curved mandible is shown in a plane. This image allows the user to evaluate the patient's mandible in a mesial-distal direction. There are two indicators in this window: the axial indicator, the red line that shows which coronal slice is seen in

the axial window and the cross indicator, the blue line that shows the localization of the nine slices seen in the cross window (Figure 3 D).

The cross-window shows a transversal reformatting image that is perpendicular to the panoramic curve. Consequently, it creates slices that are oriented in the labial-lingual direction and can be repositioned following a mesial-distal direction. The cross window is divided in nine small windows that show nine continuous slices. This window also displays two indicators that are references for the axial window (red line) and panoramic curve (green line) (Figure 3 A).

Finally, the tridimensional window shows a 3D image reformatting of the image total volume, showing only the patient's hard tissue (Figure 3 D).

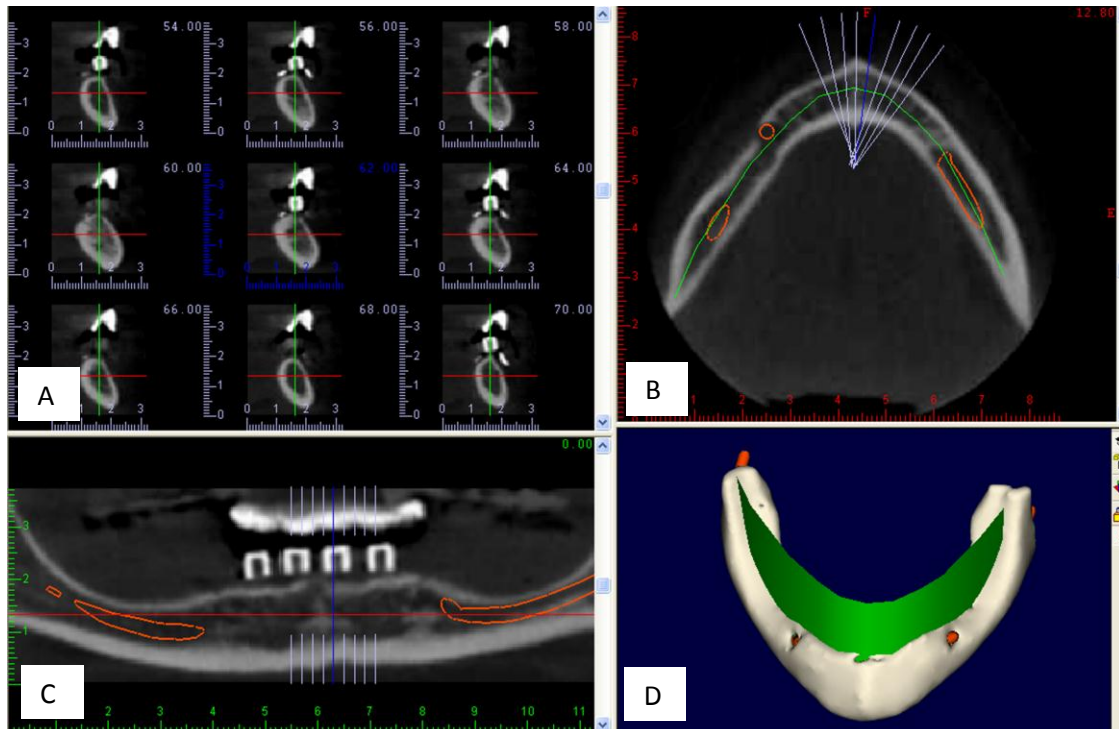
Horizontal and vertical scales are fixed in the left and inferior edges of each window. These scales, in millimeters, give the user an idea of the structures' real size during the work. It needs to be emphasized that the scales have their size updated during the zoom in and zoom out image operations, in order to keep the proportion 1:1.

From a main tool bar, an implant can be virtually inserted in the two dimensional windows (axial, cross sectional and panoramic) using the "insert implant" icon. After its insertion, the implant can also be visualized on the 3D window. The implants are inserted with their long axis perpendicular to the plane of the axial images. After their insertion, other icons named 'move implant' and "rotate implant" can be used to adjust it to a desired position, and these movements can be observed from any window. This software also features tools



for manipulation and analysis of all onscreen dataset, such as anatomic structures, volumetric analysis of bone, bone height and width. In addition, this pre-operative planning system offers predictability, precision, and communication between the clinician and patient and in-between the team members.

After the transfer of the images obtained from the CBCT scan to the software, the radiopaque images of the metal tubes, used to display the implants position and angulation, the denture's anterior teeth and the denture's base could be visualized.



**Figure 3: Computer image showing the four windows for visualization available in the Dental Slice® software:** (A) Transversal or cross sectional, with panoramic curve (green line) and axial line (red line) as indicators. (B) Axial view, with the panoramic curve (green line) and cross line (blue line) as indicators. (C) Panoramic view with the axial line (red) and cross line (blue) as indicators. (D) Tridimensional view, showing only one indicator, the panoramic curve (green plane). To make this image, the patient underwent CBCT exam with the surgical guide positioned in the mouth. The metal tubes and the duplicate denture teeth can be visualized as radiopaque marks. The inferior alveolar nerve is represented in red in the axial, panoramic and 3D views. Software Dental Slice® source: images from the study.

### **7.9. Planning the position of the implants using dental implant treatment planning software**

Using the CBCT scan and imaging software, a second treatment planning was performed by a second operator, who was blind to both the positions and angulations of the implants conventionally planned (the metal tubes images were hidden using a software's tool).

Treatment planning of the four interforaminal implants was carried out using specific tools of the Dental Slice<sup>®</sup> software and according to the following criteria:

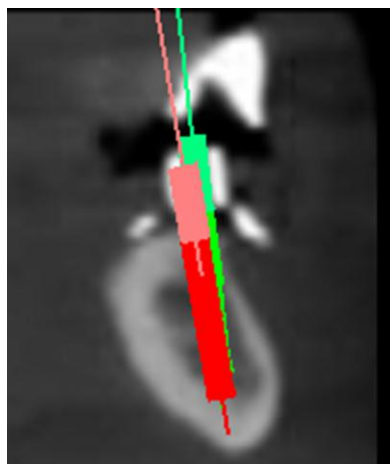
1. The implant point of entrance into the bone tissue (the bony entrance point) should be located within the confines of the buccal and lingual cortical plates of the alveolar ridge as to achieve the closest equivalent bone width on both sides of the implant at the cervical level or at least 1 mm of bone tissue surrounding the cervical area of the implant;
2. The virtual implant should be positioned into trabecular bone, with minimal or no involvement of the buccal or lingual cortical bone;
3. Osteotomies in sites with suspected arterial channels in the bone cortex, as viewed on CT scans should be avoided and, in such case, alternative sites should be searched for.
4. Following the 3M IMTEC protocol, the most distal implants should be positioned at least 7 mm anterior to the mental foramen, and all implants should keep a distance of 5 to 8 mm from each other.
5. The four implants should be parallel to each other in the frontal view.

6. There should be sufficient clearance in the denture base to accommodate one of the two attachments metal housings used in the study (4.3 or 4.75 mm in diameter, 3.3 or 3.6 mm in height) and provide a minimum of 1 mm of acrylic resin body around it.

#### **7.10. Assessing the difference in position and angulation between the implants planned with the Conventional and Software-based methods**

The four metal tubes positioned according to the Conventional method were unhidden in the CT image and their respective positions and angulations were determined with the aid of the software. Since the images of the implants originated from both methods could be seen in the same display, differences in positions and angulations could be compared and measured.

Consequently, each of the four implants virtually inserted according to the criteria that led them to be ideally positioned in relation to bone availability and prosthesis design was compared to one of the four implants positioned in the corresponding site using the Conventional method (Figure 4).



**Figure 4: Computer image showing discrepancies between two methods of implant treatment planning using the software Dental Slice®. The implant oriented with the Conventional method (green) follows the long axis of the metal tube inserted in the surgical guide (cylinder with higher radiopacity). The red cylinder represents an implant planned with the Software-based method according to criteria regarding bone availability and prosthesis design.**

Four parameters were used to compare the position of the implants oriented according to the two different methods:

1. The difference between the two implants' bony entrance points, which are the site of implants entrance in the alveolar ridge (146) , measured in the mesial-distal direction in the software's panoramic window;
2. The difference between the two implants' bony entrance points measured in the labial-lingual direction in the software's cross window;
3. The divergence of implant axis, which is the angle difference between the two implants, measured in the mesial-distal direction in the software's panoramic window;
4. The divergence of implant axis, which is the angle difference between the two implants, measured in the labial-lingual direction in the window "cross" of the software.

#### **7.10.1. Discrepancies in the bony entrance points**

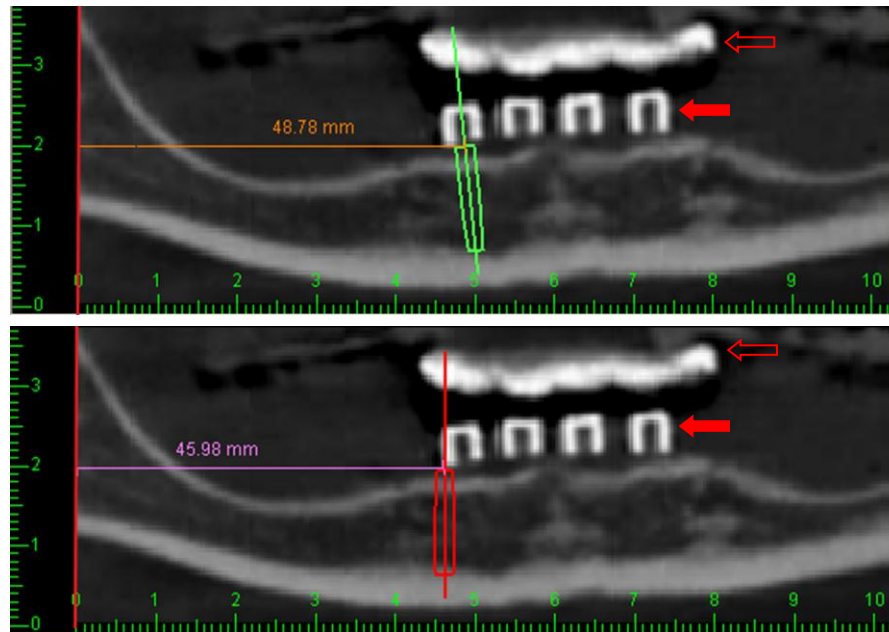
The implant's bony entrance point determined according to the Conventional method (and represented by a virtual implant inserted following the long axis of the surgical guide's metal tube in the image) was compared to the implant's bony entrance point oriented with the Software-based method. Differences of 1 mm or more were considered clinically relevant, since this is the minimal distance that could potentially harm the neighboring anatomical structures and it is considered the average accuracy in computer-aided surgical

systems (134;147;148). Differences, in millimeters, observed in the mesial-distal direction (a) and in the labial-lingual direction (b) were assessed.

a) Measuring the difference between the two implants' bony entrance points in the mesial-distal direction:

To assess these dimensions, the panoramic view was the window of choice, since it displays the mandible's image in a frontal view and shows how distally or mesially one implant is in relation to the other. As aforementioned, the software provides a scale that displays, in millimeters, the real dimension of the image in the mesial-distal direction. This horizontal fixed scale localized at the bottom of the window was used as reference for measurement; a line was drawn to delimit the zero point of the scale. A digital ruler provided as an application tool by the Dental Slice<sup>®</sup> software was used in order to perform these measurements.

The distance between the central tip of the long axis of the implant conventionally positioned and the reference line was measured. Next, the distance between the central tip of the implant long axis oriented through the software and the same reference was measured (Figure 5). Finally, the difference between the two distances was calculated.



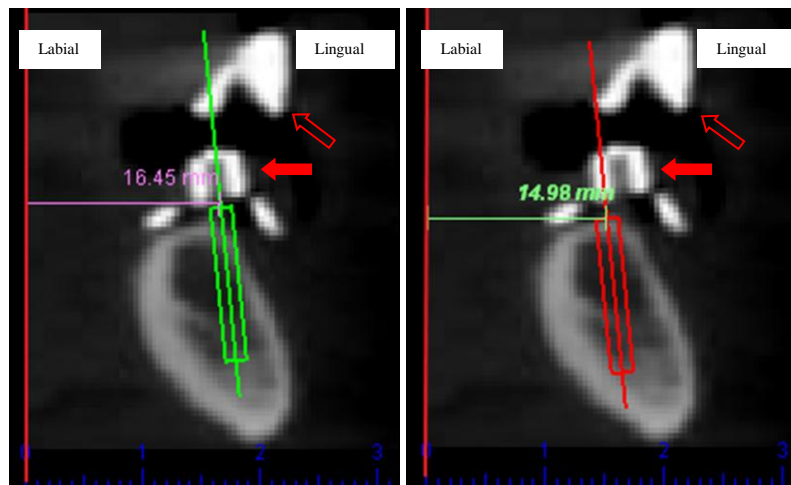
**Figure 5: Determination of the bony entrance point of the implants in the mesial-distal direction.** Above: measurement with the Conventional method (green cylinder). Below: measurement with the Software-based method (red cylinder). The radiopaque structures seen in the CBCT images above the mandibular bone (arrows) correspond to the metal tubes used as references for implants positions (solid red arrows) and simulated contour of prosthetic anterior teeth in optimal position (red outline arrows). Software Dental Slice®, source: images from the study.

b) Measuring the difference between the two implants' bony entrance points in the labial-lingual direction:

In order to assess these measurements, the cross sectional window, which shows the mandible in slices perpendicular to the panoramic curve, was the image of choice (Figure 6 A). In this window, the software provides a scale that displays, in millimeters, the real dimension of the image in the labial-lingual direction. The point zero of the horizontal scale was used as a reference for measurements. The same digital ruler used for the mesial-distal measurements was used to assess the

difference in distance between two implants oriented through the two methods and the reference line (Figures 6 A and 6 B).

Firstly, the distance between the tip of the long axis of the implant conventionally oriented and the reference line was measured. Next, the distance between the tip of the implant long axis optimally positioned with the software method and the same reference was measured (Figures 6 A and 6 B). Finally, the difference between the two distances was calculated.



**Figures 6 A (left) and 6 B (right):** Determination of the distance between the reference zero of the imaging software scale (vertical line in red) and the central tip of the long axis of the implant planned with the Conventional method (green implant) -16.45 mm - (Figure 6 A) and the central tip of the long axis of the implants oriented through the Software-based method (red implant) - 14.98 mm - (Figure 6 B). The radiopaque structures seen in the CBCT images above the mandibular bone (arrows) correspond to the metal tubes used as references for implant positions (filled arrows) and simulated contour of prosthetic anterior teeth in optimal position (empty arrows). Software Dental Slice®, source: images from the study.

The angulation of the implant oriented according to the Conventional method, represented in the scan image by a virtual implant following the metal

tube axis, was compared to the angulation of the implant axis inserted and oriented with the Software-based method for treatment planning.

In order to measure angles between the implants, additional software (PicPick, NTeWorks) was added to the CBCT image. This software provides users with a screen digital protractor, which works measuring the degree of an angle: two lines crossing each other make the protractor arms. One arm is the line from 0 to 180 degrees, called the base line of the protractor, whereas the other arm is a line from 90 and 270 degrees that intercepts the base line. This point of interception is named index or center of the protractor. These arms read the arc of an angle using a sensor, which creates electrostatics fields when activated.

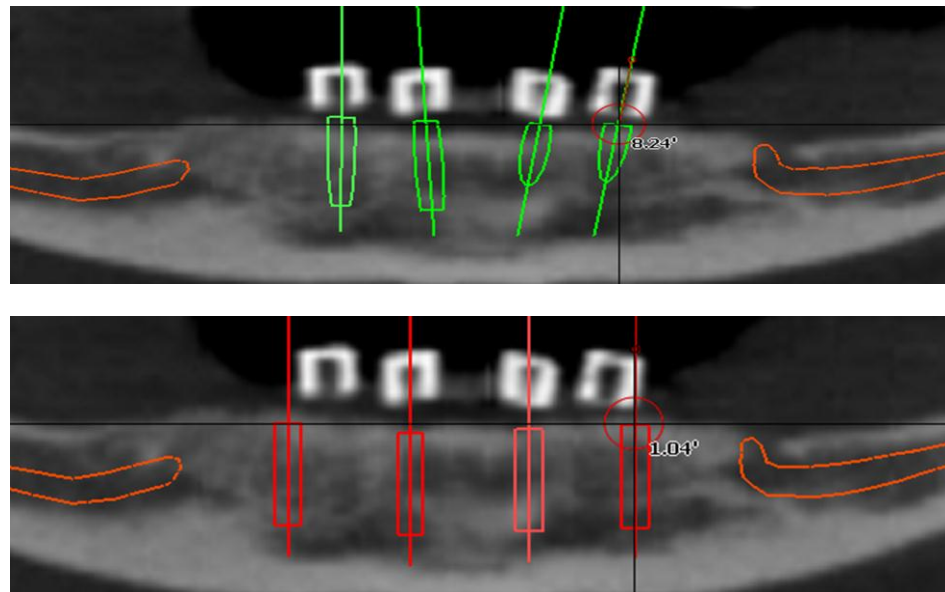
Differences of 5 degrees or more between the two implants were considered clinically relevant, since this is the minimal variation that could potentially cause anatomical hazards, such as bone dehiscence and fenestration, and it has been considered the average accuracy in computer-aided surgical systems (134;147;148). Angle differences observed in the mesial-distal (a) and labial-lingual (b) directions, in degrees, were assessed.

a) Measuring the angle difference between two implants in the mesial-distal direction:

On the CBCT image, the panoramic view was chosen to assess the measurement of the angle difference between the implants in the mesial-distal direction. First, the center of the protractor was positioned on the long axis of the implant oriented with the Conventional method. The angle between the long axis of the implant and the vertical arm of the protractor was measured and registered



(Figure 7 A). Next, the same procedure was performed to measure the angle between the long axis of the implant oriented with the Software-based method and the protractor's vertical line (Figure 7 B). Finally, the angle difference between the two implants was calculated.

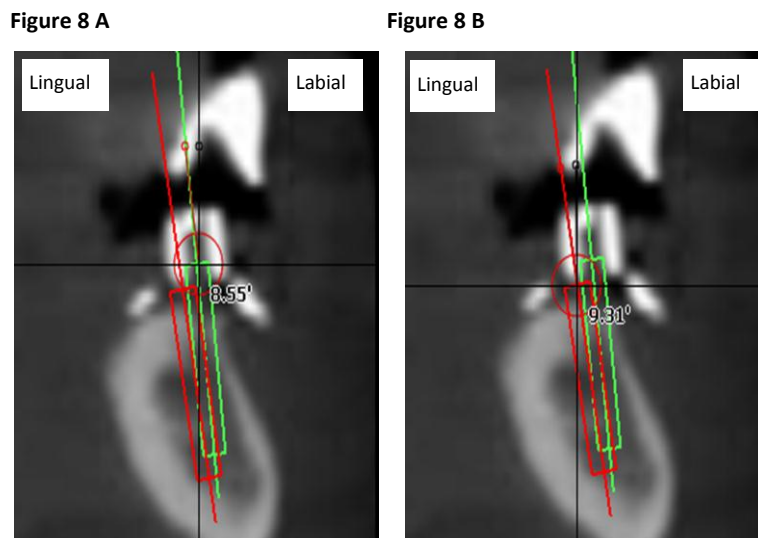


**Figures 7 A (above) and 7 B (below): Determination of the implants' angulations in the mesial-distal direction** **Figure 7 A:** angle between the long axis of an implant oriented by the Conventional method and the protractor's vertical arm (8.24 degrees). The red circle shows the protractor's point of intersection in its center. **Figure 7 B:** angle between the long axis of an implant oriented through the Software-based method (red implant) and the protractor's vertical arm (1.04 degrees). Software Dental Slice®, source: images from the study.

b) Measuring the angle difference between the two implants in the labial-lingual direction:

The same procedure of angle measurement using the digital protractor was performed to measure the angle difference between two implants in a labial-lingual direction in the software's cross window.

First, the center of the protractor was positioned on the center of the long axis of the implant oriented with the Conventional method. The angle between the long axis of the implant and the vertical arm of the protractor was measured and registered (Figure 8 A). Next, the same procedure was performed to measure the angle between the long axis of the implant oriented with the Software-based method and the protractor's vertical line (Figure 8 B). Finally, the angle difference between the two implants was calculated.



**Figures 8 A (left) and 8 B (right): Determination of the implants' angulations in the labial-lingual direction. Figure 8 A:** angle between the long axis of an implant oriented by the Conventional method (green implant) and the protractor's vertical arm (8.55 degrees). **Figure 8 B:** angle between the long axis of an implant oriented through the software-based planning (red implant) and its vertical arms (9.31 degrees). Software Dental Slice®, source: images from the study.

After measurements were performed and data were collected, the surgical guide was adjusted according to the ideal position determined by the CBCT imaging software and used during the implants placement procedure.

### **7.11. Statistical analysis**

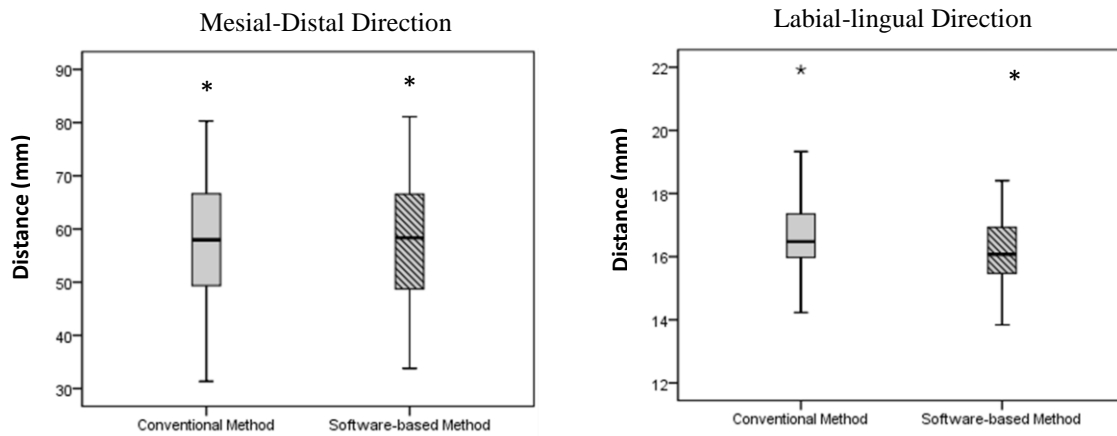
Statistical analysis was performed using R version 2.14.0 (The R foundation for Statistics Computing) and SPSS<sup>®</sup> software (Chicago, USA, 2001) for windows. Frequency distribution, median and interquartile ranges of the differences were used as descriptive values. Sample distribution was not normal, so the non-parametric Wilcoxon signed rank test for clustered data (149) was used to verify the presence of significant differences between the two methods for implants placement planning in the four parameters (bony entrance point and angle differences in mesial-distal and labial-lingual directions). The level of significance was set at the level  $p = 0.05$ .

## 8. Results

---

Treatment planning for insertion of 64 mini dental implants (MDIs) in the mandibular interforaminal area of 16 completely edentulous patients (four implants in each patient) were performed in this study. Implant diameters of 1.8 and 2.4 mm, and lengths of 10 mm and 13 mm were used according to bone volume availability.

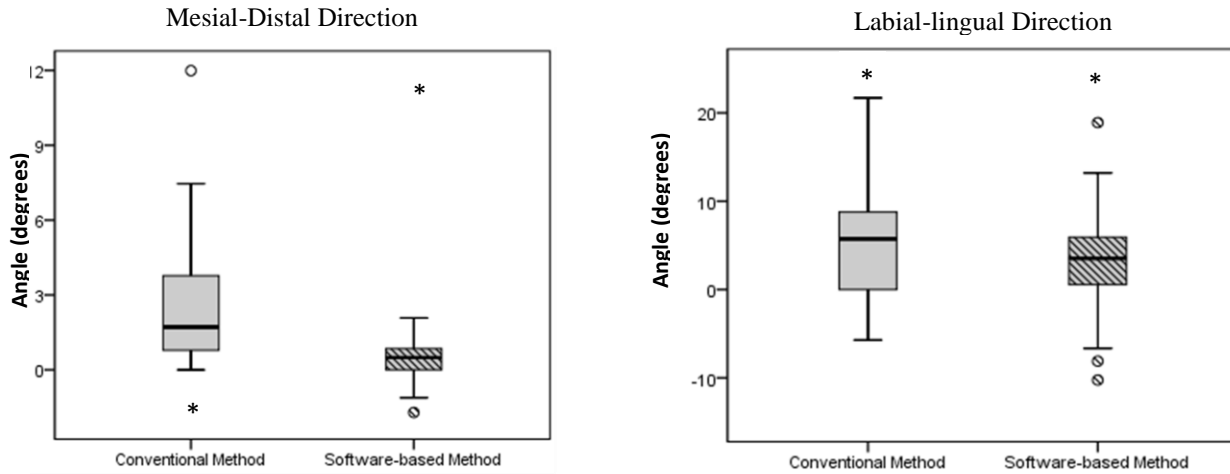
Medians and interquartile ranges (IQR) of the differences in bony entrance points between the two methods in the mesial-distal and labial-lingual aspects were, respectively, 0.8 (0.0 – 0.85) mm and 0.7 (0.0 – 5.0) mm (Figure 9).



**Figure 9:** Box plots showing median, quartiles and extreme values in millimeters for the Conventional and Software-based methods' bony entrance points in the mesial-distal and labial-lingual directions, having software's scale as reference for the measurements.

\*Statistically different ( $p < 0.05$ ; Wilcoxon signed ranked test for clustered data).

Medians (IQR) of the differences in angulations observed between the two methods were 2.2 (0.0 – 10.05) and 4.9 (0.0 – 18.7) degrees in the mesial-distal and labial-lingual directions, respectively (Figure 10). The statistical analysis demonstrated a significant difference between the two methods when comparing the bony entrance point and angulations in both mesial-distal and labial-lingual directions ( $p < 0.0001$ ).



**Figure 10:** Box plots showing median, quartiles and extreme angulation values in degrees for the Conventional Method and the Software-based Method, in the mesial-distal and labial-lingual directions.

\*Statistically different ( $p < 0.05$ ; Wilcoxon signed ranked test for clustered data).

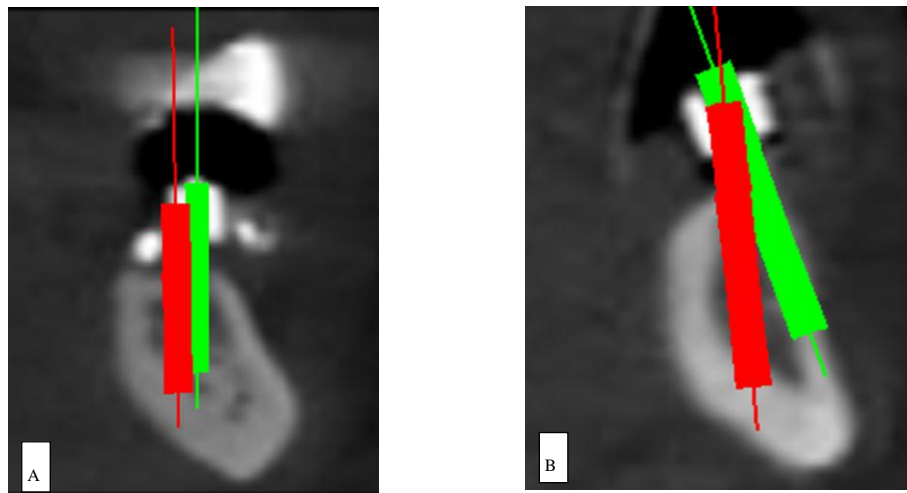
Data on bony entrance points and angulations of implants planned with the Conventional and Software-based methods are presented in Table 1.

**Table 1:** Distances between reference point in the imaging software scale and implant bony entrance points (millimeters), and implant angulations (degrees) in the mesial-distal and labial-lingual directions, determined with the Conventional and the Software-based methods.

	<i>Mesial-Distal Direction</i>			<i>Labial-Lingual Direction</i>		
	Median	Min-Max	Interquartile Range	Median	Min-Max	Interquartile Range
<i>Bony entrance points</i>						
Conventional method	57.94	33.78 – 81.94	17.78	16.47	13.95 – 21.12	1.38
Software-based method	58.34	33.78 – 81.09	17.92	16.07	15.70 – 16.89	1.48
<i>Angulations</i>						
Conventional method	1.98	0.00 – 11.99	3.47	5.03	0.00 – 21.70	7.78
Software-based method	0.71	0.00 – 1.94	0.91	4.18	0.00 – 2.80	4.85

Taking the position of implants planned with the Software-based method as reference, 35.5% of the implants (n = 24) planned with the Conventional Method were lingually positioned (median = 0.6 mm, IQR = 0.2 - 1.3 mm), and 45.8 % of the implants (n = 27) were distally positioned (median = 0.9 mm, IQR = 0.3 - 1.7 mm).

Also, it was observed that 70.3% of the implants (n = 45) planned with the Conventional Method were lingually angulated (median = 7.9°, IQR = 3.0° - 12.4°), and 86.2 % (n = 50) were distally angulated (median = 2.6°, IQR = 0.8° - 4.9°). There was no difference in angulation in six implants, when they were compared in the mesial-distal direction (Figures 11 A and B).



**Figures 11 A and B: Computer images showing discrepancies between the two methods of implant treatment planning.** The implant represented by the green cylinder, oriented according to the Conventional method, follows the long axis of the metal tube (higher radiopacity) embedded in the surgical guide. The red cylinder represents an implant oriented according to the Software-based method. **A:** image depicting a linear discrepancy in the labial-lingual direction between two implants oriented according to the two different methods. **B:** image depicting an angle discrepancy between the two implants oriented according to the two different methods.

## 9. Discussion

---

This study compared two methods of dental implant treatment planning, one based on anatomical landmarks, radiographs and casts (named “Conventional method”) and the other based on CT scans and imaging planning software. Statistically significant differences between the two methods were observed for both the bony entrance points and angulations, in both the mesial-distal and labial-lingual directions. The largest difference was observed for angulations measured in the labial-lingual direction.

The use of CBCT scans for treatment planning of dental implants has become largely recognized as a high quality, time and cost effective, imaging method (15;150;151). Several studies have confirmed that linear measurements on CBCTs images present the necessary accuracy for use in dentistry (133;152). In well controlled studies, Mozzo et al. (1998) and Moreira et al. (2009) assessed the CBCT’s geometric accuracy and reported that differences between simulated mandibular bone and dry human skulls to images generated from CBCT’s ranged from 0.15 to 2 %, for linear measurements (in width and height, respectively) and 0.33 % for angular measurements (152;153). Based on the ability of the system to reconstruct anatomic structures with dimensions considered “close to real”, the data obtained with CBCT scans were used in the present investigation as reference for comparisons with the data assessed with the Conventional method.

On the other hand, there is lack of consensus on the necessary level of accuracy for surgical guides. Among the few studies developed under this



perspective, one compared the position of implants planned with CT scans to the position of implants planned using the patient's corresponding study casts (53). Seventy-seven sites were selected for implant placement; linear discrepancies between the two methods of implant planning ranging from 0.3 mm to 0.6 mm were detected. Sample size and the linear discrepancy were similar to the ones found in the present investigation, yet, the authors did not report on angular differences between the implants; in comparison to this report, our study presented more complete data, since angular differences were also evaluated.

The data presented in this study are in agreement with previous reports. An *ex vivo* study performed by Van Asshe et al. (2007) matched pre and post-operative CT images to evaluate the accuracy of surgical guides fabricated by means of stereolithographic technique (78). Angular and linear deviations ranged from 0.7 to 4.0 degrees and from 0.3 to 2.4 mm respectively. Although the method for implant planning showed to be precise, the use of dry skulls did not allow a complete extrapolation of the differences in measurements to the clinical practice, since the soft tissue's outline could not be copied, contrarily from the present study. One could think that more sophisticated methods of surgical guide fabrication would automatically lead to a more precise device. However, the authors concluded that, in overall, any reduction in method complexity could decrease the potential miscalculations and inaccuracies.

Naitoh et al. (2000) also compared the accuracy of implants position determined with surgical guides and the abutment replica on cast models using CBCT scan images (146). Similarly to our study, transparent acrylic containing

metal tubes were fabricated and used by patients during CBCT scanning. However, instead of computer-based tools, a milling machine was used to measure differences in bony entrance points and implant angulations, which ranged from 0.5 to 1.0 mm, ranging and from 4.8 to 12.5 degrees, respectively, values that are comparable to our study.

It has been reported that a variation of 1 mm or more in the bony entrance point and of 5 degrees or more in the implant angulation can significantly affect clinical results (134;147;148). Also, surgical/prosthetic protocols for standard sized implants suggest that the distance between the implant surface and facial or lingual external surface should be of at least 1 mm in order to ensure stable hard and soft tissue conditions (154). In vivo, ex vivo and clinical studies conducted in order to verify the accuracy of different methods for dental implants planning and surgical guide fabrication have reported values close to the ones above-mentioned, being this the reason why the present study adopted those values as references for potential clinical consequences of implant treatment planning. Nevertheless, it was verified in the present study that an angular variation of 5 degrees or less in the position of the implant can lead to surgical complications such as cortical bone fenestration with damage to the surrounding tissues and potential implant loss.

The discrepancies found in the bony entrance points between the two methods in this investigation were smaller than 1 mm in both mesial-distal and labial-lingual directions, what according to those references would be considered of no clinical significance. Concurrently, differences of implant angulations observed in the mesial-distal aspect (2.6 degrees) wouldn't present major clinical

consequences either. However, when considering treatment planning for conventional dental implants, which have approximately 4 mm in diameter, even discrepancies smaller than 1 mm and 5 degrees could result in increased trans and post-surgical complications.

In contrast, differences in angles found in the labial-lingual direction (median = 7.9 degrees) were higher with the Conventional method than the limits previously proposed (5 degrees) and could cause relevant impact on the clinical outcomes. Angular differences in the same direction reached values as high as 18.7 degrees with this method, suggesting greater potential for surgical complications and implant treatment failure. Since the interforaminal mandibular bone of edentulous patients has a characteristic lingual slope in its anatomical aspect, extreme implant angulations in the labial-lingual direction would certainly lead to bone fenestration, damage to periosteum, connective tissues and vessels, with risk of hemorrhage and lack of primary implant stability (155;156).

Despite the significant topographic changes of the mandibular bone after tooth loss, the anterior mandible is considered a secure region for surgical interventions, usually involving low risk of injury to critical anatomic structures (157). However, neurovascular complications, such as hemorrhage, hematoma, trauma of the mandibular nerve and even upper airway obstruction may occur due to the lack of preoperative planning or inadequate visualization of peculiar anatomic structures, such as the mental foramen, anterior looping of the mental nerve, and the presence of terminal branches of submental and sublingual arteries that run in the direction of the lingual cortical bone (158;159). A possible

explanation for the high variation in the labial-lingual angle found in this study was the frequent occurrence of flabby ridges and concavities at the mandibular lingual cortex of edentulous patients as a consequence of the normal pattern of bone resorption. Moreover, the information provided by the intraoral examination and the panoramic radiograph performed with the Conventional method seems not have been enough for a precise assessment of the mandibular labial-lingual dimensions.

Linear differences were considered statistically significant. However, the large variation observed in the data suggests caution when interpreting this finding. Additionally, it might be relevant to consider a potential combination of linear and angular discrepancies with its clinical consequences, not only to anatomic structures but also to the results of the surgical/prosthetic treatment.

In the present study, the two methods proved to be statistically different and no hypothesis on one's superiority has been tested. However, the CT scan images of implant treatment planning with the two methods suggested higher precision in the determination of bony entrance points and angulations with the Software-based than with the Conventional method in relation to bone availability and prosthesis design. When these results are further examined in conjunction with existing findings reported in the literature, the Software-based method as described in this study seemed to provide better results, especially regarding the treatment of mandibles with advanced resorption. Conversely, the accuracy achieved with the Conventional method may suffice in clinical situations where bone availability and prosthetic limitations are not an issue and where the use of the

Software-based method may not be possible. Apart from precision, aspects of practical significance such as required skills and costs should be taken into account when choosing a method for dental implant treatment planning. The modus operandi of the Software-based method is more complex and requires a more expensive setting in comparison to the Conventional method. Other disadvantages are that this technique involves higher doses of radiation and requires professionals with expertise on the use of X-ray and imaging software.

On the other hand, less working time may be required using the Software-based method when a minimally invasive technique is implemented for dental implant insertion. Also, morbidity with dental implant therapy would be probably minimized, as less periosteal disruption is involved during the surgical procedure. Consequently, swelling, inflammation and changes in crestal bone levels would be reduced (161;162). In addition, the comprehensive assessment of bone morphology, including the evaluation of bone quality and quantity, presence of bone lesions or anatomic structures, and the width and inclination of the alveolar ridge, can increase by far the success rates of the treatment with dental implants using the Software-based method (163).

Currently, dental implants have been considered the upmost acceptable and viable treatment option for edentate patients, so clinicians have been challenged with increasingly complex and unpredictable outcomes. In this study, CT scans combined with imaging software have shown to produce more reliable results in the treatment planning for dental implants than a conventional method based on anatomical landmarks, radiographs and casts.

## 10. Conclusions

---

Within the limitations of this study, it was concluded that:

- Planning the placement of implants using Software-based methods lead to significantly different implant locations and angulations in relation to conventional planning, based on anatomical landmarks.
- Discrepancies observed in the bony entrance point, although statistically significant, might not be large enough to influence clinical outcomes.
- Statistical differences in implant angulations indicated by the two treatment planning methods, especially in the labial-lingual direction, were considered to be clinically significant.
- The Conventional method, although currently used in general practice, does not seem to be a method precise enough for implant treatment planning, especially in cases of atrophic mandibles.

## 11. Reference List

---

- (1) Simon H. Use of transitional implants to support a surgical guide: enhancing the accuracy of implant placement. J Prosthet Dent 2002 Feb;87(2):229-32.
- (2) Porter JA, von Fraunhofer JA. Success or failure of dental implants? A literature review with treatment considerations. Gen Dent 2005 Nov;53(6):423-32.
- (3) Ganz SD. Computer-aided design/computer-aided manufacturing applications using CT and cone beam CT scanning technology. Dent Clin North Am 2008 Oct;52(4):777-808, vii.
- (4) Wulfman C, Hadida A, Rignon-Bret C. Radiographic and surgical guide fabrication for implant-retained mandibular overdenture. J Prosthet Dent 2010 Jan;103(1):53-7.
- (5) Garber DA. The esthetic dental implant: letting restoration be the guide. J Oral Implantol 1996;22(1):45-50.
- (6) Garber DA, Belser UC. Restoration-driven implant placement with restoration-generated site development. Compend Contin Educ Dent 1995 Aug;16(8):796, 798-802, 804.
- (7) Adrian ED, Ivanhoe JR, Krantz WA. Trajectory surgical guide stent for implant placement. J Prosthet Dent 1992 May;67(5):687-91.
- (8) Caplanis N, Kan JY, Lozada JL. Osseointegration: contemporary concepts and treatment. J Calif Dent Assoc 1997 Dec;25(12):843-51.

- (9) Young L, Jr., Gatewood RR, Moore DJ, Sakumura JS. Surgical templates for immediate denture insertion. J Prosthet Dent 1985 Jul;54(1):64-7.
- (10) Bavar T. A new twist on surgical guides. J Oral Implantol 2008;34(6):325-9.
- (11) Parel SM, Funk JJ. The use and fabrication of a self-retaining surgical guide for controlled implant placement: a technical note. Int J Oral Maxillofac Implants 1991;6(2):207-10.
- (12) Cowan PW. Surgical templates for the placement of osseointegrated implants. J Ir Dent Assoc 1991;37(1):10-5.
- (13) Edge MJ. Surgical placement guide for use with osseointegrated implants. J Prosthet Dent 1987 Jun;57(6):719-22.
- (14) Burns DR, Crabtree DG, Bell DH. Template for positioning and angulation of intraosseous implants. J Prosthet Dent 1988 Oct;60(4):479-83.
- (15) Guerrero ME, Jacobs R, Loubele M, Schutyser F, Suetens P, van SD. State-of-the-art on cone beam CT imaging for preoperative planning of implant placement. Clin Oral Investig 2006 Mar;10(1):1-7.
- (16) Minoretti R, Merz BR, Triaca A. Predetermined implant positioning by means of a novel guide template technique. Clin Oral Implants Res 2000 Jun;11(3):266-72.
- (17) Sicilia A, Noguerol B, Cobo J, Zabalegui I. Profile surgical template: a systematic approach to precise implant placement. A



technical note. Int J Oral Maxillofac Implants 1998 Jan;13(1):109-14.

- (18) Vercruyssen M, Jacobs R, Van AN, van SD. The use of CT scan based planning for oral rehabilitation by means of implants and its transfer to the surgical field: a critical review on accuracy. J Oral Rehabil 2008 Jun;35(6):454-74.
- (19) Tarlow JL. Fabrication of an implant surgical stent for the edentulous mandible. J Prosthet Dent 1992 Feb;67(2):217-8.
- (20) Neidlinger J, Lilien BA, Kalant DC, Sr. Surgical implant stent: a design modification and simplified fabrication technique. J Prosthet Dent 1993 Jan;69(1):70-2.
- (21) Espinosa MJ, Alvarez AA, Pardo CA, Fernandez Vazquez JP, Ibaseta DG. Fabrication of an implant radiologic-surgical stent for the partially edentulous patient. Quintessence Int 1995 Feb;26(2):111-4.
- (22) Walker M, Hansen P. Dual-purpose, radiographic-surgical implant template: fabrication technique. Gen Dent 1999 Mar;47(2):206-8.
- (23) Tsuchida F, Hosoi T, Imanaka M, Kobayashi K. A technique for making a diagnostic and surgical template. J Prosthet Dent 2004 Apr;91(4):395-7.
- (24) Balshi TJ, Garver DG. Surgical guidestents for placement of implants. J Oral Maxillofac Surg 1987 May;45(5):463-5.
- (25) Engelman MJ, Sorensen JA, Moy P. Optimum placement of osseointegrated implants. J Prosthet Dent 1988 Apr;59(4):467-73.

- (26) Mizrahi B, Thunthy KH, Finger I. Radiographic/surgical template incorporating metal telescopic tubes for accurate implant placement. *Pract Periodontics Aesthet Dent* 1998 Aug;10(6):757-65.
- (27) Almog DM, Torrado E, Meitner SW. Fabrication of imaging and surgical guides for dental implants. *J Prosthet Dent* 2001 May;85(5):504-8.
- (28) Yeh S, Monaco EA, Buhite RJ. Using transitional implants as fixation screws to stabilize a surgical template for accurate implant placement: a clinical report. *J Prosthet Dent* 2005 Jun;93(6):509-13.
- (29) Simon H. Use of transitional implants to support a surgical guide: enhancing the accuracy of implant placement. *J Prosthet Dent* 2002 Feb;87(2):229-32.
- (30) Sicilia A, Enrile FJ, Buitrago P, Zubizarreta J. Evaluation of the precision obtained with a fixed surgical template in the placement of implants for rehabilitation of the completely edentulous maxilla: a clinical report. *Int J Oral Maxillofac Implants* 2000 Mar;15(2):272-7.
- (31) Aalam AA, Reshad M, Chee WW, Nowzari H. Surgical template stabilization with transitional implants in the treatment of the edentulous mandible: a technical note. *Int J Oral Maxillofac Implants* 2005 May;20(3):462-5.
- (32) Wu AY, Chee W. Use of 3 transitional implants as stabilization aid for predictable immediate loading of implants in the edentulous mandible. *Quintessence Int* 2006 Sep;37(8):627-31.

- (33) Petrungaro PS, Windmiller N. Using transitional implants during the healing phase of implant reconstruction. *Gen Dent* 2001 Jan;49(1):46-51.
- (34) Reddy MS, Mayfield-Donahoo T, Vanderven FJ, Jeffcoat MK. A comparison of the diagnostic advantages of panoramic radiography and computed tomography scanning for placement of root form dental implants. *Clin Oral Implants Res* 1994 Dec;5(4):229-38.
- (35) Vazquez L, Nizam Al DY, Christoph BU, Combescure C, Bernard JP. Reliability of the vertical magnification factor on panoramic radiographs: clinical implications for posterior mandibular implants. *Clin Oral Implants Res* 2011 Mar 21.
- (36) Lagravere MO, Carey J, Toogood RW, Major PW. Three-dimensional accuracy of measurements made with software on cone-beam computed tomography images. *Am J Orthod Dentofacial Orthop* 2008 Jul;134(1):112-6.
- (37) Hausmann E. Hausmann,E. *J Periodontol* 2000 Mar;71(3):497-503.
- (38) Jacobs R. Dental cone beam CT and its justified use in oral health care. *JBR -BTR* 2011 Sep;94(5):254-65.
- (39) Dawood A, Brown J, Sauret-Jackson V, Purkayastha S. Optimization of cone beam CT exposure for pre-surgical evaluation of the implant site. *Dentomaxillofac Radiol* 2012 Jan;41(1):70-4.
- (40) Maher MM, Kalra MK, Toth TL, Wittram C, Saini S, Shepard J. Application of rational practice and technical advances for

optimizing radiation dose for chest CT. J Thorac Imaging 2004 Jan;19(1):16-23.

- (41) Kalra MK, Maher MM, Toth TL, Hamberg LM, Blake MA, Shepard JA, et al. Strategies for CT radiation dose optimization. Radiology 2004 Mar;230(3):619-28.
- (42) McCollough CH, Primak AN, Braun N, Kofler J, Yu L, Christner J. Strategies for reducing radiation dose in CT. Radiol Clin North Am 2009 Jan;47(1):27-40.
- (43) Drage N, Carmichael F, Brown J. Radiation protection: protection of patients undergoing cone beam computed tomography examinations. Dent Update 2010 Oct;37(8):542-8.
- (44) Schorn C, Visser H, Hermann KP, Alamo L, Funke M, Grabbe E. Dental-CT: Image quality and absorbed radiation dose of different scan protocols. Rofo-Fortschritte Auf dem Gebiet der Rontgenstrahlen und der Bildgebenden Verfahren 1999;170(2):137-44.
- (45) Worthington P, Rubenstein J, Hatcher DC. The role of cone-beam computed tomography in the planning and placement of implants. J Am Dent Assoc 2010 Oct;141 Suppl 3:19S-24S.
- (46) Hall EJ, Brenner DJ. Cancer risks from diagnostic radiology. Br J Radiol 2008 May;81(965):362-78.
- (47) Modica F, Fava C, Benecch A, Preti G. Radiologic-prosthetic planning of the surgical phase of the treatment of edentulism by osseointegrated implants: an in vitro study. J Prosthet Dent 1991 Apr;65(4):541-6.

- (48) Israelson H, Plemons JM, Watkins P, Sory C. Barium-coated surgical stents and computer-assisted tomography in the preoperative assessment of dental implant patients. The International journal of periodontics & restorative dentistry 12 (1) (pp 52-61), 1992 Date of Publication: 1992 1992;(1):1992.
- (49) Klein M, Cranin AN, Sirakian A. A computerized tomography (CT) scan appliance for optimal presurgical and preprosthetic planning of the implant patient. Practical periodontics and aesthetic dentistry : PPAD 5 (6) (pp 33-39; quiz 39), 1993 Date of Publication: Aug 1993 1993;(6):Aug.
- (50) Verde MA, Morgano SM. A dual-purpose stent for the implant-supported prosthesis. J Prosthet Dent 1993 Mar;69(3):276-80.
- (51) Kopp KC, Koslow AH, Abdo OS. Predictable implant placement with a diagnostic/surgical template and advanced radiographic imaging. J Prosthet Dent 2003 Jun;89(6):611-5.
- (52) Wat PY, Chow TW, Luk HW, Comfort MB. Precision surgical template for implant placement: a new systematic approach. Clin Implant Dent Relat Res 2002;4(2):88-92.
- (53) Besimo CE, Lambrecht JT, Guindy JS. Accuracy of implant treatment planning utilizing template-guided reformatted computed tomography. Dento maxillo facial radiology 29 (1) (pp 46-51), 2000 Date of Publication: Jan 2000(1):Jan.
- (54) Lofthag-Hansen S. Cone beam computed tomography radiation dose and image quality assessments. Swed Dent J Suppl 2009;(209):4-55.

- (55) Palomo L, Palomo JM. Cone beam CT for diagnosis and treatment planning in trauma cases. *Dent Clin North Am* 2009 Oct;53(4):717-vii.
- (56) Yajima A, Otonari-Yamamoto M, Sano T, Hayakawa Y, Otonari T, Tanabe K, et al. Cone-beam CT (CB Throne) applied to dentomaxillofacial region. *Bull Tokyo Dent Coll* 2006 Aug;47(3):133-41.
- (57) Isoda K, Ayukawa Y, Tsukiyama Y, Sogo M, Matsushita Y, Koyano K. Relationship between the bone density estimated by cone-beam computed tomography and the primary stability of dental implants. *Clin Oral Implants Res* 2011 May 5.
- (58) Fuster-Torres MA, Penarrocha-Diago M, Penarrocha-Oltra D, Penarrocha-Diago M. Relationships between bone density values from cone beam computed tomography, maximum insertion torque, and resonance frequency analysis at implant placement: a pilot study. *Int J Oral Maxillofac Implants* 2011 Sep;26(5):1051-6.
- (59) Marquezan M, Lau TC, Mattos CT, Cunha AC, Nojima LI, Sant'Anna EF, et al. Bone mineral density. *Angle Orthod* 2012 Jan;82(1):62-6.
- (60) Gonzalez-Garcia R, Monje F. The reliability of cone-beam computed tomography to assess bone density at dental implant recipient sites: a histomorphometric analysis by micro-CT. *Clin Oral Implants Res* 2012 Jan 17.
- (61) Hohlweg-Majert B, Pautke C, Deppe H, Metzger MC, Wagner K, Schulze D. Qualitative and quantitative evaluation of bony

structures based on DICOM dataset. J Oral Maxillofac Surg 2011 Nov;69(11):2763-70.

- (62) Goiato MC, Santos MR, Pesqueira AA, Moreno A, dos Santos DM, Haddad MF. Prototyping for surgical and prosthetic treatment. J Craniofac Surg 2011 May;22(3):914-7.
- (63) Esses SJ, Berman P, Bloom AI, Sosna J. Clinical applications of physical 3D models derived from MDCT data and created by rapid prototyping. AJR Am J Roentgenol 2011 Jun;196(6):W683-W688.
- (64) Garg AK, Vicari A. Radiographic modalities for diagnosis and treatment planning in implant dentistry. Implant Soc 1995;5(5):7-11.
- (65) Jensen J, Simonsen EK, Sindet-Pedersen S. Reconstruction of the severely resorbed maxilla with bone grafting and osseointegrated implants: a preliminary report. J Oral Maxillofac Surg 1990 Jan;48(1):27-32.
- (66) Balshi SF, Wolfinger GJ, Balshi TJ. Surgical planning and prosthesis construction using computed tomography, CAD/CAM technology, and the Internet for immediate loading of dental implants. J Esthet Restor Dent 2006;18(6):312-23.
- (67) Witkowski S, Lange R. [Stereolithography as an additive technique in dentistry]. Schweiz Monatsschr Zahnmed 2003;113(8):868-84.
- (68) Marchack CB, Moy PK. The use of a custom template for immediate loading with the definitive prosthesis: a clinical report. J Calif Dent Assoc 2003 Dec;31(12):925-9.

- (69) Parel SM, Triplett RG. Interactive imaging for implant planning, placement, and prosthesis construction. *J Oral Maxillofac Surg* 2004 Sep;62(9 Suppl 2):41-7.
- (70) Becker W, Doerr J. Three-dimensional software for fabrication of a surgical template and final implant-supported restoration for a fully edentulous maxilla: a case report. *Compend Contin Educ Dent* 2005 Nov;26(11):802, 804-2, 807.
- (71) Fortin T, Champleboux G, Lormee J, Coudert JL. Precise dental implant placement in bone using surgical guides in conjunction with medical imaging techniques. *J Oral Implantol* 2000;26(4):300-3.
- (72) Fortin T, Bosson JL, Coudert JL, Isidori M. Reliability of preoperative planning of an image-guided system for oral implant placement based on 3-dimensional images: an in vivo study. *Int J Oral Maxillofac Implants* 2003 Nov;18(6):886-93.
- (73) D'haese J, Van D, V, Komiyama A, Hultin M, De BH. Accuracy and Complications Using Computer-Designed Stereolithographic Surgical Guides for Oral Rehabilitation by Means of Dental Implants: A Review of the Literature. *Clin Implant Dent Relat Res* 2010 May 11.
- (74) Cassetta M, Giansanti M, Di MA, Calasso S, Barbato E. Accuracy of Two Stereolithographic Surgical Templates: A Retrospective Study. *Clin Implant Dent Relat Res* 2011 Jul 11.
- (75) Ozan O, Turkyilmaz I, Ersoy AE, McGlumphy EA, Rosenstiel SF. Clinical accuracy of 3 different types of computed tomography-



derived stereolithographic surgical guides in implant placement. J Oral Maxillofac Surg 2009 Feb;67(2):394-401.

- (76) Arisan V, Karabuda ZC, Ozdemir T. Accuracy of two stereolithographic guide systems for computer-aided implant placement: a computed tomography-based clinical comparative study. J Periodontol 2010 Jan;81(1):43-51.
- (77) Bentz RM, Balshi SF. Complete oral rehabilitation with implants using CAD/CAM technology, stereolithography, and conoscopic holography. Implant Dent 2012 Feb;21(1):8-12.
- (78) Van AN, van SD, Guerrero ME, Hirsch E, Schutyser F, Quirynen M, et al. Accuracy of implant placement based on pre-surgical planning of three-dimensional cone-beam images: a pilot study. J Clin Periodontol 2007 Sep;34(9):816-21.
- (79) Ersoy AE, Turkeyilmaz I, Ozan O, McGlumphy EA. Reliability of implant placement with stereolithographic surgical guides generated from computed tomography: clinical data from 94 implants. J Periodontol 2008 Aug;79(8):1339-45.
- (80) Jensen J, Sindet-Pedersen S. Autogenous mandibular bone grafts and osseointegrated implants for reconstruction of the severely atrophied maxilla: a preliminary report. J Oral Maxillofac Surg 1991 Dec;49(12):1277-87.
- (81) Erickson DM, Chance D, Schmitt S, Mathis J. An opinion survey of reported benefits from the use of stereolithographic models. J Oral Maxillofac Surg 1999 Sep;57(9):1040-3.
- (82) Wulf J, Vitt KD, Erben CM, Bill JS, Busch LC. Medical biomodelling in surgical applications: results of a multicentric

European validation of 466 cases. Stud Health Technol Inform 2003;94:404-6.

- (83) Birkfellner W, Solar P, Gahleitner A, Huber K, Kainberger F, Kettenbach J, et al. In-vitro assessment of a registration protocol for image guided implant dentistry. Clin Oral Implants Res 2001 Feb;12(1):69-78.
- (84) Kelly PJ. State of the Art and Future Directions of Minimally Invasive Stereotactic Neurosurgery. Cancer Control 1995 Jul;2(4):287-92.
- (85) Gunkel AR, Freysinger W, Thumfart WF. Experience with various 3-dimensional navigation systems in head and neck surgery. Arch Otolaryngol Head Neck Surg 2000 Mar;126(3):390-5.
- (86) Wagner A, Rasse M, Millesi W, Ewers R. Virtual reality for orthognathic surgery: the augmented reality environment concept. J Oral Maxillofac Surg 1997 May;55(5):456-62.
- (87) Siessegger M, Mischkowski RA, Schneider BT, Krug B, Klesper B, Zoller JE. Image guided surgical navigation for removal of foreign bodies in the head and neck. J Craniomaxillofac Surg 2001 Dec;29(6):321-5.
- (88) Wagner A, Ploder O, Enislidis G, Truppe M, Ewers R. Virtual image guided navigation in tumor surgery--technical innovation. J Craniomaxillofac Surg 1995 Oct;23(5):217-3.
- (89) Hassfeld S, Zoller J, Albert FK, Wirtz CR, Knauth M, Muhling J. Preoperative planning and intraoperative navigation in skull base surgery. J Craniomaxillofac Surg 1998 Aug;26(4):220-5.

- (90) Suess O, Kombos T, Kurth R, Suess S, Mularski S, Hammersen S, et al. Intracranial image-guided neurosurgery: experience with a new electromagnetic navigation system. *Acta Neurochir (Wien)* 2001 Sep;143(9):927-34.
- (91) Wagner A, Ploder O, Enislidis G, Truppe M, Ewers R. Image-guided surgery. *Int J Oral Maxillofac Surg* 1996 Apr;25(2):147-51.
- (92) Ecke U, Gosepath J, Mann WJ. Initial experience with intraoperative ultrasound in navigated soft tissue operations of the neck and below the base of the skull. *Ultraschall Med* 2006 Feb;27(1):49-54.
- (93) Helbig M, Krysztoforski K, Kroll T, Kucharski J, Popek M, Helbig S, et al. Navigation-supported and sonographically-controlled fine-needle puncture in soft tissues of the neck. *Ultrasound Med Biol* 2009 Mar;35(3):436-42.
- (94) Hassfeld, Brief, Raczkowsky, Marmulla, Mende, Ziegler. Computer-based approaches for maxillofacial interventions. *Minim Invasive Ther Allied Technol* 2003 Mar;12(1):25-35.
- (95) Metson RB, Cosenza MJ, Cunningham MJ, Randolph GW. Physician experience with an optical image guidance system for sinus surgery. *Laryngoscope* 2000 Jun;110(6):972-6.
- (96) Siessegger M, Schneider BT, Mischkowski RA, Lazar F, Krug B, Klesper B, et al. Use of an image-guided navigation system in dental implant surgery in anatomically complex operation sites. *J Craniomaxillofac Surg* 2001 Oct;29(5):276-81.
- (97) Verstreken K, Van CJ, Marchal G, Naert I, Suetens P, van SD. Computer-assisted planning of oral implant surgery: a three-

dimensional approach. *Int J Oral Maxillofac Implants* 1996 Nov;11(6):806-10.

- (98) Fortin T, Coudert JL, Champeboux G, Sautot P, Lavallee S. Computer-assisted dental implant surgery using computed tomography. *J Image Guid Surg* 1995;1(1):53-8.
- (99) Holst S, Blatz MB, Eitner S. Precision for computer-guided implant placement: using 3D planning software and fixed intraoral reference points. *J Oral Maxillofac Surg* 2007 Mar;65(3):393-9.
- (100) Arisan V, Karabuda ZC, Piskin B, Ozdemir T. Conventional Multi-Slice Computed Tomography (CT) and Cone-Beam CT (CBCT) for Computer-Aided Implant Placement. Part II: Reliability of Mucosa-Supported Stereolithographic Guides. *Clin Implant Dent Relat Res* 2012 Jan 11.
- (101) Meloni SM, De RG, Pisano M, Massarelli O, Tullio A. Computer assisted dental rehabilitation in free flaps reconstructed jaws: one year follow-up of a prospective clinical study. *Br J Oral Maxillofac Surg* 2012 Jan 10.
- (102) Vrielinck L, Politis C, Schepers S, Pauwels M, Naert I. Image-based planning and clinical validation of zygoma and pterygoid implant placement in patients with severe bone atrophy using customized drill guides. Preliminary results from a prospective clinical follow-up study. *Int J Oral Maxillofac Surg* 2003 Feb;32(1):7-14.
- (103) Miller RJ, Bier J. Surgical navigation in oral implantology. *Implant Dent* 2006 Mar;15(1):41-7.

- (104) Widmann G, Widmann R, Stoffner R, Widmann E, Rieger T, Remensberger S, et al. Multipurpose navigation system-based concept for surgical template production. *J Oral Maxillofac Surg* 2009 May;67(5):1113-20.
- (105) Ozan O, Turkyilmaz I, Yilmaz B. A preliminary report of patients treated with early loaded implants using computerized tomography-guided surgical stents: flapless versus conventional flapped surgery. *J Oral Rehabil* 2007 Nov;34(11):835-40.
- (106) Azari A, Nikzad S. Flapless implant surgery: review of the literature and report of 2 cases with computer-guided surgical approach. *J Oral Maxillofac Surg* 2008 May;66(5):1015-21.
- (107) Casap N, Tarazi E, Wexler A, Sonnenfeld U, Lustmann J. Intraoperative computerized navigation for flapless implant surgery and immediate loading in the edentulous mandible. *Int J Oral Maxillofac Implants* 2005 Jan;20(1):92-8.
- (108) Oh TJ, Shotwell J, Billy E, Byun HY, Wang HL. Flapless implant surgery in the esthetic region: advantages and precautions. *Int J Periodontics Restorative Dent* 2007 Feb;27(1):27-33.
- (109) Cannizzaro G, Leone M, Consolo U, Ferri V, Esposito M. Immediate functional loading of implants placed with flapless surgery versus conventional implants in partially edentulous patients: a 3-year randomized controlled clinical trial. *Int J Oral Maxillofac Implants* 2008 Sep;23(5):867-75.
- (110) Becker W, Goldstein M, Becker BE, Sennerby L. Minimally invasive flapless implant surgery: a prospective multicenter study. *Clin Implant Dent Relat Res* 2005;7 Suppl 1:S21-S27.

- (111) Brodala N. Flapless surgery and its effect on dental implant outcomes. *Int J Oral Maxillofac Implants* 2009;24 Suppl:118-25.
- (112) Campelo LD, Camara JR. Flapless implant surgery: a 10-year clinical retrospective analysis. *Int J Oral Maxillofac Implants* 2002 Mar;17(2):271-6.
- (113) Bidra AS. Consequences of insufficient treatment planning for flapless implant surgery for a mandibular overdenture: a clinical report. *J Prosthet Dent* 2011 May;105(5):286-91.
- (114) Nikzad S, Azari A. Custom-made radiographic template, computed tomography, and computer-assisted flapless surgery for treatment planning in partial edentulous patients: a prospective 12-month study. *J Oral Maxillofac Surg* 2010 Jun;68(6):1353-9.
- (115) Berdougou M, Fortin T, Blanchet E, Isidori M, Bosson JL. Flapless implant surgery using an image-guided system. A 1- to 4-year retrospective multicenter comparative clinical study. *Clinical Implant Dentistry & Related Research* 2010 Jun 1;12(2):142-52.
- (116) Fortin T, Bosson JL, Isidori M, Blanchet E. Effect of flapless surgery on pain experienced in implant placement using an image-guided system. *Int J Oral Maxillofac Implants* 2006 Mar;21(2):298-304.
- (117) Azari A, Nikzad S. Flapless implant surgery: review of the literature and report of 2 cases with computer-guided surgical approach. *J Oral Maxillofac Surg* 2008 May;66(5):1015-21.
- (118) Malo P, de Araujo NM, Lopes A. The use of computer-guided flapless implant surgery and four implants placed in immediate function to support a fixed denture: preliminary results after a

mean follow-up period of thirteen months. J Prosthet Dent 2007 Jun;97(6 Suppl):S26-S34.

- (119) Sohrabi K, Mushantat A, Esfandiari S, Feine J. How successful are small-diameter implants? A literature review. Clin Oral Implants Res 2012 Feb 7.
- (120) Mazor Z, Steigmann M, Leshem R, Peleg M. Mini-implants to reconstruct missing teeth in severe ridge deficiency and small interdental space: a 5-year case series. Implant Dent 2004 Dec;13(4):336-41.
- (121) Odman J, Grondahl K, Lekholm U, Thilander B. The effect of osseointegrated implants on the dento-alveolar development. A clinical and radiographic study in growing pigs. Eur J Orthod 1991 Aug;13(4):279-86.
- (122) Huang LH, Shotwell JL, Wang HL. Dental implants for orthodontic anchorage. Am J Orthod Dentofacial Orthop 2005 Jun;127(6):713-22.
- (123) Kwon KR, Sachdeo A, Weber HP. Achieving immediate function with provisional prostheses after implant placement: a clinical report. J Prosthet Dent 2005 Jun;93(6):514-7.
- (124) Ohkubo C, Kobayashi M, Suzuki Y, Sato J, Hosoi T, Kurtz KS. Evaluation of transitional implant stabilized overdentures: a case series report. J Oral Rehabil 2006 Jun;33(6):416-22.
- (125) Petrungaro PS, Windmiller N. Using transitional implants during the healing phase of implant reconstruction. Gen Dent 2001 Jan;49(1):46-51.

- (126) Vigolo P, Givani A, Majzoub Z, Cordioli G. Clinical evaluation of small-diameter implants in single-tooth and multiple-implant restorations: a 7-year retrospective study. *Int J Oral Maxillofac Implants* 2004 Sep;19(5):703-9.
- (127) Raghoobar GM, Schoen P, Meijer HJ, Stellingsma K, Vissink A. Early loading of endosseous implants in the augmented maxilla: a 1-year prospective study. *Clin Oral Implants Res* 2003 Dec;14(6):697-702.
- (128) Babbush CA, Kent JN, Misiek DJ. Titanium plasma-sprayed (TPS) screw implants for the reconstruction of the edentulous mandible. *J Oral Maxillofac Surg* 1986 Apr;44(4):274-82.
- (129) Dilek O, Tezulas E, Dincel M. Required minimum primary stability and torque values for immediate loading of mini dental implants: an experimental study in nonviable bovine femoral bone. *Oral Surg Oral Med Oral Pathol Oral Radiol Endod* 2008 Feb;105(2):e20-e27.
- (130) Griffiths TM, Collins CP, Collins PC. Mini dental implants: an adjunct for retention, stability, and comfort for the edentulous patient. *Oral Surg Oral Med Oral Pathol Oral Radiol Endod* 2005 Nov;100(5):e81-e84.
- (131) Ahn MR, An KM, Choi JH, Sohn DS. Immediate loading with mini dental implants in the fully edentulous mandible. *Implant Dent* 2004 Dec;13(4):367-72.
- (132) Bulard RA, Vance JB. Multi-clinic evaluation using mini-dental implants for long-term denture stabilization: a preliminary



biometric evaluation. *Compend Contin Educ Dent* 2005 Dec;26(12):892-7.

- (133) Lascala CA, Panella J, Marques MM. Analysis of the accuracy of linear measurements obtained by cone beam computed tomography (CBCT-NewTom). *Dentomaxillofac Radiol* 2004 Sep;33(5):291-4.
- (134) Ersoy AE, Turkyilmaz I, Ozan O, McGlumphy EA. Reliability of implant placement with stereolithographic surgical guides generated from computed tomography: Clinical data from 94 implants. *Journal of Periodontology* 2008 Aug;79(8):1339-45.
- (135) McArdle BF. A technique to enhance closed surgical stents for implant placement. *Journal of the American Dental Association* (1939) 133 (3) (pp 331-333), 2002 Date of Publication: Mar 2002(1939):Mar.
- (136) Cehreli MC, Aslan Y, Sahin S. Bilaminar dual-purpose stent for placement of dental implants. *J Prosthet Dent* 2000 Jul;84(1):55-8.
- (137) Cehreli MC, Sahin S. Fabrication of a dual-purpose surgical template for correct labiopalatal positioning of dental implants. *Int J Oral Maxillofac Implants* 2000 Mar;15(2):278-82.
- (138) Solow RA. Simplified radiographic-surgical template for placement of multiple, parallel implants. *J Prosthet Dent* 2001 Jan;85(1):26-9.
- (139) Minoretti R, Merz BR, Triaca A. Predetermined implant positioning by means of a novel guide template technique. *Clin Oral Implants Res* 2000 Jun;11(3):266-72.

- (140) [http://multimedia.3m.com/mws/mediawebserver?mwsId=66666UuZjcFSLXTtnxf2OXMVEVuQEcuZgVs6EVs6E666666--&fn=MDI\\_Protocols.pdf](http://multimedia.3m.com/mws/mediawebserver?mwsId=66666UuZjcFSLXTtnxf2OXMVEVuQEcuZgVs6EVs6E666666--&fn=MDI_Protocols.pdf). 2011. Ref Type: Generic
- (141) [http://www.straumann.ca/15x\\_754\\_surgical\\_procedure.pdf](http://www.straumann.ca/15x_754_surgical_procedure.pdf)
- (142) Flanagan D, Mascolo A. The mini dental implant in fixed and removable prosthetics: a review. J Oral Implantol 2011 Mar;37 Spec No:123-32.
- (143) Shatkin TE, Shatkin S, Oppenheimer AJ, Oppenheimer BD. A simplified approach to implant dentistry with mini dental implants. Alpha Omegan 2003 Oct;96(3):7-15.
- (144) Bulard RA, Vance JB. Multi-clinic evaluation using mini-dental implants for long-term denture stabilization: a preliminary biometric evaluation. Compend Contin Educ Dent 2005 Dec;26(12):892-7.
- (145) Batenburg RH, Meijer HJ, Raghoobar GM, Vissink A. Treatment concept for mandibular overdentures supported by endosseous implants: a literature review. Int J Oral Maxillofac Implants 1998 Jul;13(4):539-45.
- (146) Naitoh M, Aiji E, Okumura S, Ohsaki C, Kurita K, Ishigami T. Can implants be correctly angulated based on surgical templates used for osseointegrated dental implants? Clin Oral Implants Res 2000 Oct;11(5):409-14.
- (147) Nickenig HJ, Wichmann M, Hamel J, Schlegel KA, Eitner S. Evaluation of the difference in accuracy between implant placement by virtual planning data and surgical guide templates versus the conventional free-hand method - a combined in vivo -

in vitro technique using cone-beam CT (Part II). J Craniomaxillofac Surg 2010 Oct;38(7):488-93.

- (148) Besimo CE, Lambrecht JT, Guindy JS. Accuracy of implant treatment planning utilizing template-guided reformatted computed tomography. Dentomaxillofac Radiol 2000 Jan;29(1):46-51.
- (149) Rosner B, Glynn RJ, Lee ML. The Wilcoxon signed rank test for paired comparisons of clustered data. Biometrics 2006 Mar;62(1):185-92.
- (150) Araki K, Maki K, Seki K, Sakamaki K, Harata Y, Sakaino R, et al. Characteristics of a newly developed dentomaxillofacial X-ray cone beam CT scanner (CB MercuRay): system configuration and physical properties. Dentomaxillofac Radiol 2004 Jan;33(1):51-9.
- (151) Loubele M, Maes F, Schutyser F, Marchal G, Jacobs R, Suetens P. Assessment of bone segmentation quality of cone-beam CT versus multislice spiral CT: a pilot study. Oral Surg Oral Med Oral Pathol Oral Radiol Endod 2006 Aug;102(2):225-34.
- (152) Mozzo P, Procacci C, Tacconi A, Martini PT, Andreis IA. A new volumetric CT machine for dental imaging based on the cone-beam technique: preliminary results. Eur Radiol 1998;8(9):1558-64.
- (153) Moreira CR, Sales MA, Lopes PM, Cavalcanti MG. Assessment of linear and angular measurements on three-dimensional cone-beam computed tomographic images. Oral Surg Oral Med Oral Pathol Oral Radiol Endod 2009 Sep;108(3):430-6.
- (154) [http://www.straumann.ca/15x\\_754\\_surgical\\_procedure.pdf](http://www.straumann.ca/15x_754_surgical_procedure.pdf)

- (155) Wittwer G, Adeyemo WL, Schicho K, Figl M, Enislidis G. Navigated flapless transmucosal implant placement in the mandible: a pilot study in 20 patients. *Int J Oral Maxillofac Implants* 2007 Sep;22(5):801-7.
- (156) Quirynen M, Mraiwa N, van SD, Jacobs R. Morphology and dimensions of the mandibular jaw bone in the interforaminal region in patients requiring implants in the distal areas. *Clin Oral Implants Res* 2003 Jun;14(3):280-5.
- (157) Park SH, Wang HL. Implant reversible complications: classification and treatments. *Implant Dent* 2005 Sep;14(3):211-20.
- (158) Cawood JI, Howell RA. A classification of the edentulous jaws. *Int J Oral Maxillofac Surg* 1988 Aug;17(4):232-6.
- (159) Al-Ani O, Nambiar P, Ha KO, Ngeow WC. Safe zone for bone harvesting from the interforaminal region of the mandible. *Clin Oral Implants Res* 2012 Jan 11.
- (160) Kramer FJ, Baethge C, Swennen G, Rosahl S. Navigated vs. conventional implant insertion for maxillary single tooth replacement. *Clin Oral Implants Res* 2005 Feb;16(1):60-8.
- (161) Becker W, Goldstein M, Becker BE, Sennerby L. Minimally invasive flapless implant surgery: a prospective multicenter study. *Clin Implant Dent Relat Res* 2005;7 Suppl 1:S21-S27.
- (162) Bayounis AM, Alzoman HA, Jansen JA, Babay N. Healing of peri-implant tissues after flapless and flapped implant installation. *J Clin Periodontol* 2011 Aug;38(8):754-61.

- (163) Frederiksen NL. Diagnostic imaging in dental implantology. Oral Surg Oral Med Oral Pathol Oral Radiol Endod 1995 Nov;80(5):540-54.
-